



Diagonistic Value of ARFI in Breast Lesions

J. Jayapriya^a and S. Arul Murugan^{a*}

^a Department of General Medicine, Sri Lakshmi Narayana Institute of Medical Sciences, Bharath Institute of Higher Education and Research, Chennai, Tamilnadu, India.

Authors' contributions

This work was carried out in collaboration between both authors. Both authors read and approved the final manuscript.

Article Information

DOI: 10.9734/JPRI/2021/v33i50B33421

Editor(s):

(1) Dr. Thomas F. George, University of Missouri- St. Louis, USA.

Reviewers:

(1) Tan Xiao Jian, Tunku Abdul Rahman University College, Malaysia.

(2) Moumena Salah Yassen, University of Mosul, Iraq.

Complete Peer review History: <https://www.sdiarticle4.com/review-history/73709>

Original Research Article

Received 05 September 2021

Accepted 13 November 2021

Published 18 November 2021

ABSTRACT

Breast cancer became the most prominent cancer type in women worldwide. Its prevalence increased in recent years due to changes in life style and relapse among the patients seemed to be higher. Acoustic radiation force impulse (ARFI) imaging in based on the principle of the ultrasonic elasticity and the elastography accurately predict and measure the changes in breast cancer tissue compared to the normal tissue. It is a technical alternative to the palpation and able to measure lesser than 10 mm size. In contrast to biopsy, where the reduced deformability would occur and lead to biopsy failing. In fibroadenoma, due to its complications, many false positives could be detected and the ARFI elastography serve as an effective alternative method for breast cancer confirmation. The tissue stiffness index value is used to differentiate the benign and malignant tissue samples. ARFI further, use B- mode elasticity and help in recommending the biopsy confirmation.

Keywords: ARFI; elastography; tissue stiffness; benign; malignant; b-mode.

1. INTRODUCTION

Breast cancer is one for the most prevalent cancer in women and it is the leading most cause

for cancer related death in women population worldwide. It was estimated that every year, 1.7 million cases are registered newly and 521,900 deaths are recorded. It is accounted for

*Corresponding author: E-mail: drsarulmurugan@yahoo.com;

approximately, 25% of cancer patients suffering from breast cancer and it caused 15% cancer related death among the patients. The Breast ultrasound elastography is one of the recent developments in imaging the breast cancer tissues and it is based on the sonographic principle with conventional ultrasonography (US) and mammography. It is used to identify the tissue stiffness and could be used as a valuable non-invasive method for predicting the cancer tissues. It is working under B-mode ultrasound sonography technique [1,2,3,4]. The breast cancer lump is formed due to many hostile physiological reasons and helps in validating the stages of the breast cancer. The minute benign tumor could escape from the mammography, but, the ultrasonography could accurately detect those minute breast cancer tumors [1].

The qualified sonograms could be derived from the 5 -10- MHz linear transducers and the associated imaging of the lesions are within the transducer focus that characteristically with the compensation curve based on the time-gain method. The US technique could use to different the cancer tissues from the polyps and require a minute amount of the tissues in comparing with other methods.

The current elastography has extended the usage by specific detection of the USG and aiding in the breast cancer diagnosis. The elastography with shear wave elastography (SE) is used to further differentiate the cancer tissues and the associated correction for accurate prediction based on Stavros criteria (stages 3 and 4 BI- RADS).

The shear wave method used to distinguish between the benign and malignant lesions in comparing with the surrounding tissues. Usually, the malignant tissues are harder than the

surround tissues [5]. The significant values are predicted using ARFI techniques and SR assessment for identifying the lesions [6-7]. The other most important technique, BUS also uses the sonography advantages. The present study aimed to analyse the SE participation on malignant detection. The complication of benign tissues seemed to be in their sizes, since, they are alike the surrounding tissues by differing within a minute variation in diameters [7,8]. The aim of present research study was to appraise whether the combination of BUS, ARFI elastography, and SR improves the diagnostic performance of differentiating malignant and benign breast lesions.

2. METHODOLOGY

Based on the INCLUSION CRITERIA and EXCLUSION CRITERIA patients were following up and samples were collected. Patients were diagnosed with benign or malignant lesions by using biopsy sampling.

2.1 Methods Used for Data Collection

In the present study, the patients identified with the focal lesions (either cystic or solid type) were further assessed with the B-mode USG techniques based on the SE/ ARFI principles. The Siemens ACUSON S 2000 ultrasound system was used for the study and the scoring adopted for the previous study [9]. The samples were assessed and the data was further analyzed using the Student T test for its statistical evaluation. The properties such as ROC curve, specificity, and sensitivity, positive and negative predictive values were calculated. The scores were for benign was between 1-3 and 4 or 5 for malignant, respectively using receiver operator characteristic (ROC) analysis ($p < 0.05$, was considered to be significant).

3. RESULTS AND DISCUSSION

Table 1. The score based on VTI for differentiating the benign lesions Crosstab

VTI Benign	HPE-Benign		Total
Positive count % of total	34	1	35
	68.0%	2.0%	70.0%
Negative count of % of total	1	14	15
	2.0%	28.0%	30.0%
Total	35	15	50
	70.0%	30.05	100.0%

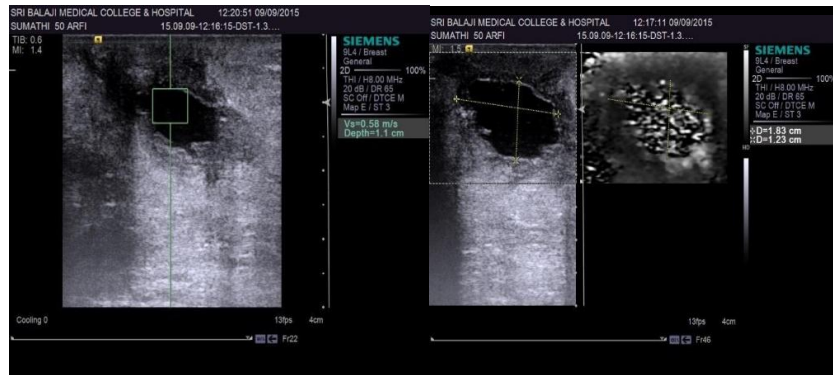


Fig. 1 The ARFI values for Cystic breast lesions using shear wave velocity

Its value was near approximately from zero to 1 in VTI method. (Figs. 1-6).

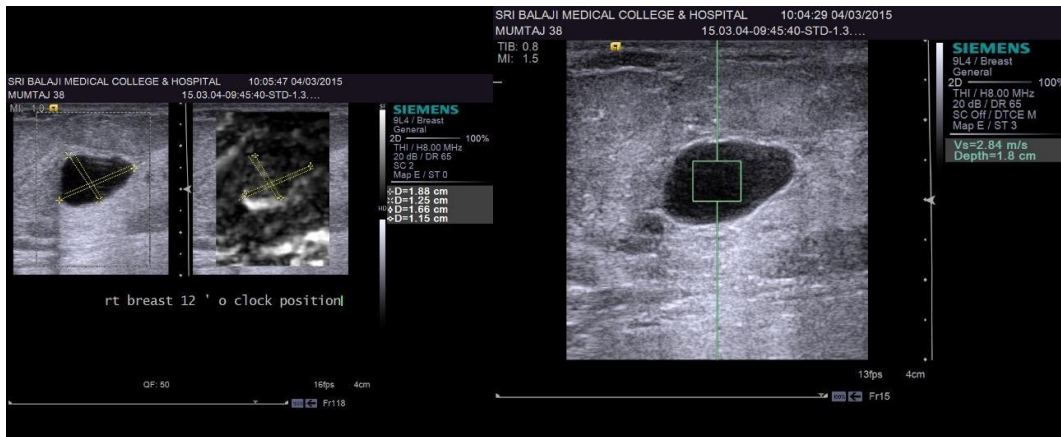


Fig. 2. The ARFI value for Cystic breast lesions without the internal registrations

Table 2. The accuracy of VTI method for confirming the malignant lesions Crosstab

VTQ- Malignant	HPE- Malignant		Total
Positive Count % of Total	16	6	24
Negative Count % of Total	32 %	16%	46%
Total	0%	52%	52%
	16	34	50
	32%	68%	100%

3.1 ROC Curve

The results, as were graphically represented as a comparison of VTQ and VTI methods for identifying the malignant lesions using Receiver operating characteristic (ROC).

1 - Specificity

The ties produced the diagonal segments and the associated blue line was represented by the VTI. The respective green line indicated the VTQ presence.

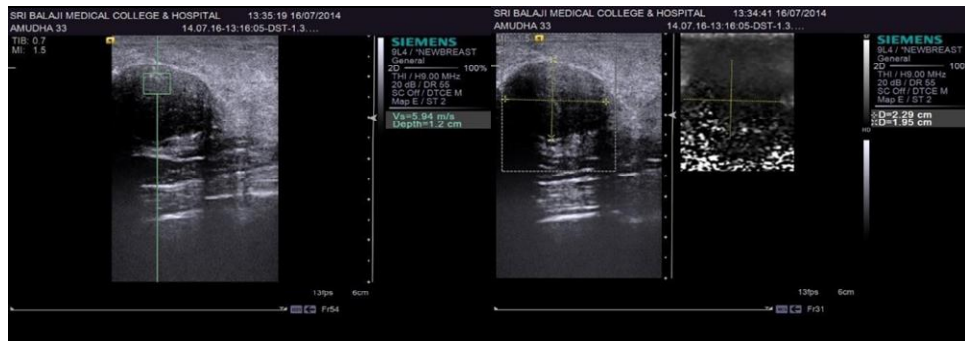


Fig. 3. ARFI score for Cystic breast lesions without internal registrations

Table 3. The statistical analysis of the sampled data

	N	Minimum	Maximum	Mean	Std. Deviation
AGE	50	15	71	40.56	13.958
Valid N (list wise)	50				

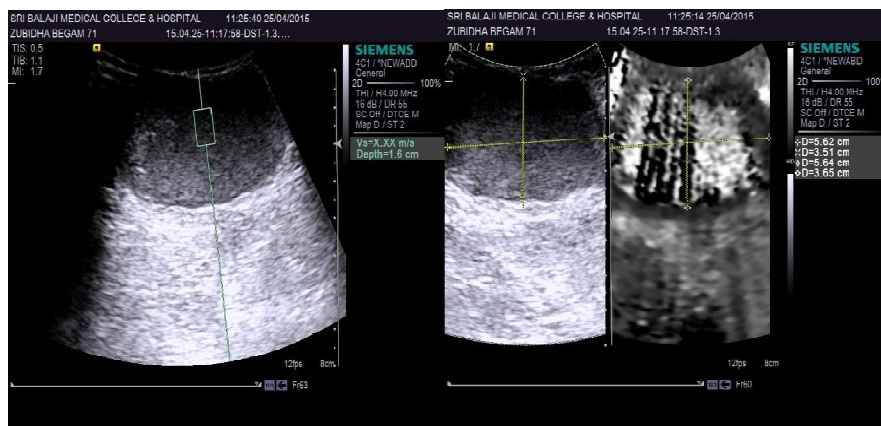


Fig. 4. The lesions were scored with B-mode between 4 to 5 using VTL method

Table 4. AGE * VTQ - Malignant Crosstab

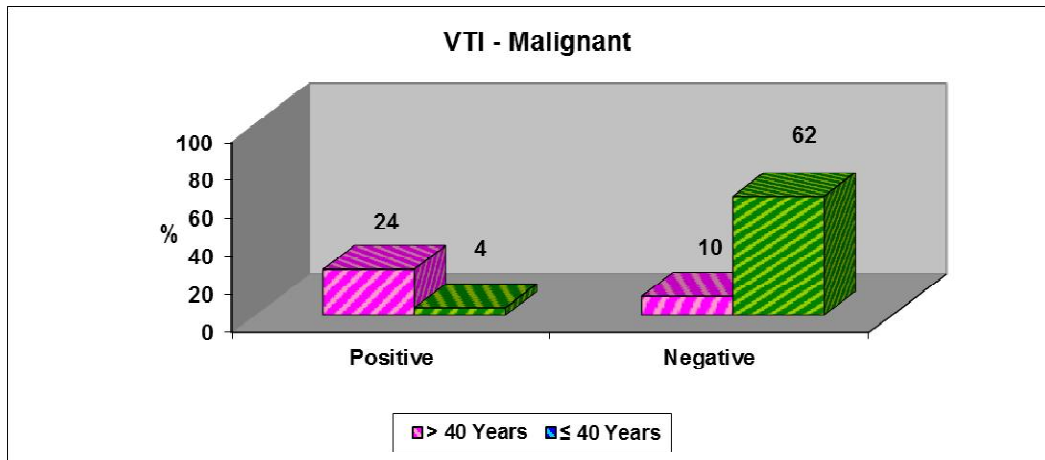
		VTQ - Malignant		Total
		Positive	Negative e	
AGE	>40 YEARS Count	13	4	17
	% of Total	26.0%	8.0%	34.0%
	<=40YEARS Count	11	22	33
	% of Total	22.0%	44.0%	66.0%
Total Count		24	26	50
% of Total		48.0%	52.0%	100.0%

50 patients were selected for the study. Of them, 34 and 16 were diagnosed with benign and malignant respectively. Among them, 31 patients were lesser than forty years and other 16 were higher than 40 years. The prevalence of the malignant tumor was found to be higher in patients with greater than 40 years and the benign tumors

were frequently found in patients lesser than 40 years. The VTI evaluation showed that the method had nearly 97% sensitivity and 93% specificity, respectively. The 87.5 % sensitivity samples used with of VT method had 100% specificity for PPV based malignant lesions detection. Nearly, other 71.4 % sensitivity

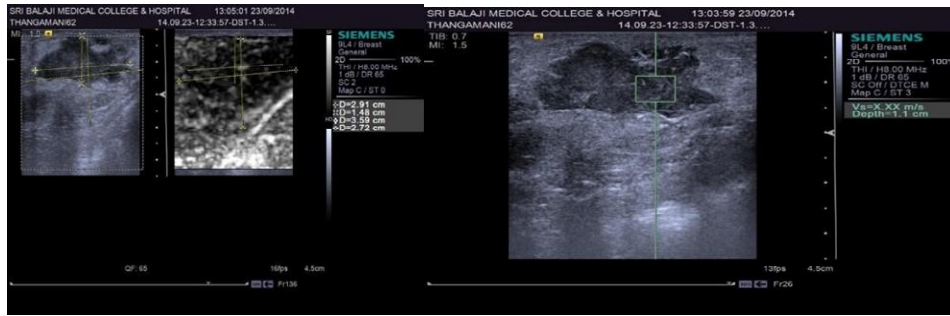

Fig. 5. The lesions were scored with B-mode between 6 to 7 in VTI.



	Positive	Negative
>40 Years	24	10
≤40 Years	4	62

Fig. 6. Malignant detection using VT among the patient with 40 years age

samples showed that 100% specificity using PPV detection. The present study showed there was a significant difference between theta and VTQ type of imaging for detecting the benign and malignant lesions (p value < 0.001 derived from Table 3). The VTI dependent on the VTQ technique for lesion detection and both of them were similarly reliable for confirming the lesions in breast cancer samples. Hence routine ultrasound with ARFI connection improves the imaging diagnostic accuracy in categorizing benign and malignant breast lesions.

The breast cancer seems to be with highest prevalent among the women worldwide and leading most cause for cancer related deaths. The US-based elastography ARFI accurately detects the lesions and able to differ the benign and malignant stages. It is a quantitative and semi-quantitative method that can able to work without any intrusiveness or radiation technology.

In the present study, ARFI method was appraised and showed to have higher sensitivity and specificity in diagnosing the malignant and benign breast lesions [10]. Real-time elastography further share the possibility of additional characters that enhance the detection than the conventional US [11, 12].

It had the ability to differ between the cystic polyps and benign tumors using internal registered (ARFI/ SE) echo imaging. Usually, the lesions seemed to be with bright echoes in VTI method. If typical cystic features on elasticity modes are combined with benign features on B-Mode imaging, FNA could be avoided [13-16]. In the present study, sample size was comparatively small and need to be explored in further study for accurate evaluation as reported by the previous study [12]. The pre compression step certainly has important effect on determining the dimensions and need to be standardized for

the practical usage [17, 9]. Further technical advances may overcome this limitation in the future.

4. CONCLUSION

US elastography was able to find the fine details such as location, lesion size, lesion depth, and pathologic feature that were associated with the benign or malignant forms. Thus, the US elastography is one of the auspicious techniques for detecting the breast cancer lesions with minute diameter.

CONSENT

As per international standard or university standard, patient's written consent has been collected and preserved by the author(s).

ETHICAL APPROVAL

The study was approved by the Institutional Ethics Committee and preserved by the author(s).

ACKNOWLEDGEMENTS

The encouragement and support from Bharath University, Chennai is gratefully acknowledged. For provided the laboratory facilities to carry out the research work.

COMPETING INTERESTS

Authors have declared that no competing interests exist.

REFERENCES

1. Goodia Bonardi M, Alessi S. Breast Elastography: A literature review, Journal Of Ultrasound. 2012;15(3):192-198. Elsevier Masson Italy
2. Balleyguier C, Canale S, Ben Hassen W, Vielh P, Bayou EH, Mathieu MC, Uzan C, Bourcier C, Dromain C. Breast elasticity: principles, technique, results: an update and overview of commercially available software. Eur J Radiol. 2013;82(3):427-34.
3. Li DD, Guo LH, Xu HX, Liu C, Xu JM, Sun LP, Wu J, Liu BJ, Liu LN, Xu XH. Acoustic radiation force impulse elastography for differentiation of malignant and benign breast lesions: a meta-analysis. Int. J. Clin Exp Med. 2015;8(4):4753-61.
4. Hiltawsky KM, Kruger M, Starke C, Heuser L, Ermert H, Jensen A. Freehand ultrasound elastography of breast lesions: clinical results. Ultrasound Med Biol. 2001; 27:1461-1469.
5. Itoh A, Ueno E, Tohno E, Kamma H, Takahashi H, Shiina T, Yamakawa M, Matsumura T. Breast disease: Clinical application of US elastography for diagnosis. Radiology. 2006;239:341-350.
6. Li G, Li DW, Fang YX, Song YJ, Deng ZJ, Gao J, Xie Y, Yin TS, Ying L, Tang KF. Performance of shear wave elastography for differentiation of benign and malignant solid breast masses. PLoS One. 2013;8: 76322.
7. Sadigh G, Carlos RC, Neal CH, Dwamena BA. Accuracy of quantitative ultrasound elastography for differentiation of malignant and benign breast abnormalities: a meta-analysis. Breast Cancer Res Treat. 2012;134:923-931.
8. Lyschik A, Higashi T, Asato R, Tanaka S, Ito J, Hiraoka M. Cervical lymph node metastases: Diagnosis at sonoelastography—initial experience. Radiology. 2007;243:258-267.
9. Itoh A, Ueno E, Tohno E, Kamma H, Takahashi H, Shiina T. Breast disease: Clinical application of US elastography for diagnosis. Radiology. 2006;239:341-350.
10. Aigner F, De Zordo T, Pallwein-Prettner L, Junker D, Schäfer G, Pichler R. Real-time sonoelastography for the evaluation of testicular lesions. Radiology. 2012;263: 584- 589.
11. Nightingale K, Bentley R, Trahey G. Observations of tissue response to acoustic radiation force: opportunities for imaging. Ultrason Imaging. 2002;24:129-138.
12. Nightingale K, Stutz D, Bentley R, Trahey G. Acoustic radiation force impulse imaging: ex vivo and in vivo demonstration of transient shear wave propagation. Biomed Imag. 2002:525-528. Conference Publications.
13. Hoyt K, Parker KJ, Rubens DJ. Real-time shear velocity imaging using sonoelastographic techniques. Ultrasound Med Biol. 2007;33:1086-1097.
14. Shiina T, Nitta N, Ueno E, Bamber JC. Real time tissue elasticity imaging using the combined auto correlation method. J Med Ultrason. 2002;29:119-128.
15. Nightingale K, Soo MS, Nightingale R, Bentley R, Trahey G. In vivo demonstration

- of acoustic radiation force impulse (ARFI) imaging in the thyroid, abdomen, and breast. Ultrasonics symposium. IEEE. 2001;2:1633–1638.
16. Nightingale K, Soo MS, Nightingale R, Bentley R, Stutz D, Palmeri M. Acoustic radiation force impulse imaging: remote palpation of the mechanical properties of tissue. Ultrasonics symposium. IEEE. 2002;2:1821–1830.
17. Bercoff J, Tanter M, Fink M. Supersonic shear imaging: A new technique for soft tissue elasticity mapping. IEEE Trans Ultrason Ferroelectr Freq Control. 2004;51:396–409.

© 2021 Jayapriya and Murugan; This is an Open Access article distributed under the terms of the Creative Commons Attribution License (<http://creativecommons.org/licenses/by/4.0>), which permits unrestricted use, distribution, and reproduction in any medium, provided the original work is properly cited.

Peer-review history:
The peer review history for this paper can be accessed here:
<https://www.sdiarticle4.com/review-history/73709>