



Case Report

Unusual presentations of acute kidney injury and neurologic complications due to snake bite

Hamid Noshad¹, Reza Rikhtegar*², Mehdi Hagdoost³, Masood Dinevari⁴, Hosein Mahmoodi⁵

¹ Professor, Chronic Kidney Disease Research Center, Sina Hospital, Tabriz University of Medical Sciences, Tabriz, Iran

² Assistant Professor, Neuroscience Research Centre, Imam Reza Hospital, Tabriz University of Medical Sciences, Tabriz, Iran

³ Assistant Professor, Department of Infectious Disease, School of Medicine, Sina Hospital, Tabriz University of Medical Sciences, Tabriz, Iran

⁴ Assistant Professor, Liver and Gastrointestinal Disease Research Center, Tabriz University of Medical Sciences, Tabriz, Iran

⁵ Student of Medicine, Islamic Azad University, Tabriz Branch, Tabriz, Iran

Article info

Article History:

Received: 15 Mar. 2015

Accepted: 06 May. 2015

ePublished: 09 June. 2015

Keywords:

Acute Kidney Injury,
Posterior Reversible
Encephalopathy,
Snake Bite

Abstract

Introduction: Vascularity of kidneys is very high, so these organs are potentially susceptible to be affected with toxins including snake venom. Hypersensitivity to snake venom could cause some neurological problem.

Case Report: We present a 14-year-old boy with acute kidney injury (AKI) due to snake bite. After a few days, kidney failure with hematuria was developed. His serum creatinine level rose to 3 mg/dl and following 2 weeks gradually and decreased to normal level without any special treatment except for anti-venom, which was not prescribed in appropriate time (this type of AKI is not reported previously). He had seizure attacks, which were according to magnetic resonance imaging due to posterior reversible encephalopathy syndrome (PRES) (This neurologic complication has been seen in other kidney injuries but up to now it was not reported in snake bite victims).

Conclusion: Snake venom could cause PRES due to AKI and seizure could be one of the most important complications in snake bite.

Citation: Noshad H, Rikhtegar R, Hagdoost M, Dinevari M, Mahmoodi H. **Unusual presentations of acute kidney injury and neurologic complications due to snake bite.** *J Anal Res Clin Med* 2015; 3(2): 126-8.

Introduction

Vascularity of kidneys is very high, so these organs are potentially susceptible to be affected with toxins, including snake venom. Renal involvement has so many different features such as proteinuria, hematuria and renal failure.¹ Renal damage may be the reason of hypovolemia and hypoperfusion, thrombotic microangiopathy, rhabdomyolysis and of venom cytotoxicity on the renal tubules.² Glomerular lesions are not seen frequently, but there are rare reports of proliferative and rapidly progressive glomerulonephritis.³ A direct cytotoxic effect on the kidney may occur. However, it is still not documented with other studies. Hypersensitivity to venomous or anti-venomous protein occasionally causes

acute renal failure.⁴

Case Report

A 14-year-old boy presented due to snake bite. He had abdominal pain and was admitted to infectious disease ward. His initial vital signs and lab exams were normal, and there were not any petechiae or purpura. He had not any previous history of renal disease. A peripheral blood smear was normal. Creatine kinase level was normal, and there was not any evidence of hemolysis. Fever was low grade (38 °C) and the blood pressure was 150/80 mmHg. Urine examination revealed dysmorphic red blood cells (RBCs) (without casts) so glomerulonephritis was considered.

* Corresponding Author: Reza Rikhtegar, Email: reza_rikhtegar@yahoo.com

© 2015 The Authors; Tabriz University of Medical Sciences

This is an Open Access article distributed under the terms of the Creative Commons Attribution License (<http://creativecommons.org/licenses/by/3.0>), which permits unrestricted use, distribution, and reproduction in any medium, provided the original work is properly cited.

Creatinine level rose to more than 3 mg/dl. Four vials of anti-venom were infused. Lab examination results were as below: Urine volume: 2800 cc/24 h, protein in urine: +3 (1530 mg) erythrocyte sedimentation rate: 80 mm, prothrombin time (PT): 15 s, international normalized ratio: 1.5, platelet: 210000, hepatitis B core antibody: (Negative), hepatitis B surface antigen: (Negative), Cr: 2.7 mg/dl, urea: 239 mg/dl, white blood cell (WBC): 10900, albumin: 2.8 g/dl, anti-nuclear antibodies: (Negative), antistreptolysin O (ASO): 250 u, antineutrophil cytoplasmic antibody: (Negative), C3 and C4: decreased. Kidney biopsy was planned, but it was not allowed by patient's parent. His urea and creatinine level got better during next days. 7 days thereafter an episode of tonic colonic seizure happened. Magnetic resonance imaging (MRI) were ordered. Bilateral hypersignal areas in the occipital region were detected (Figure 1).

According to MRI, posterior reversible encephalopathy syndrome (PRES) was considered, and sodium-valproate started. He was discharged with normal serum

creatinine and urea level (0.7 and 34 mg/dl respectively). 3 weeks after discharge, there was not any evidence of edema. Creatinine and urea level again was normal. Urine analysis revealed mild hematuria (6-8 RBCs).

Discussion

Usual systemic manifestations of snake bite are hemolysis, rhabdomyolysis, hypotension and shock which may lead to renal damage and may be kidney failure.⁵

The renal histology mainly consists of acute tubular necrosis and acute interstitial nephritis, while glomerular changes are rare.¹ Abdominal pain is a common feature. The presence of abdominal pain and its severity is correlated with the severity of coagulopathy, neurotoxicity, kidney involvement.⁶ It was detected in our patient.

Acute kidney injury (AKI) developed in 31.0% of patients with snake bite, leading to mortality in 39.1% patients. Factors associated with AKI are a bite to hospital time, hypotension, albuminuria, prolonged bleeding time, prolonged PT, low hemoglobin and a high total bilirubin,⁷ which

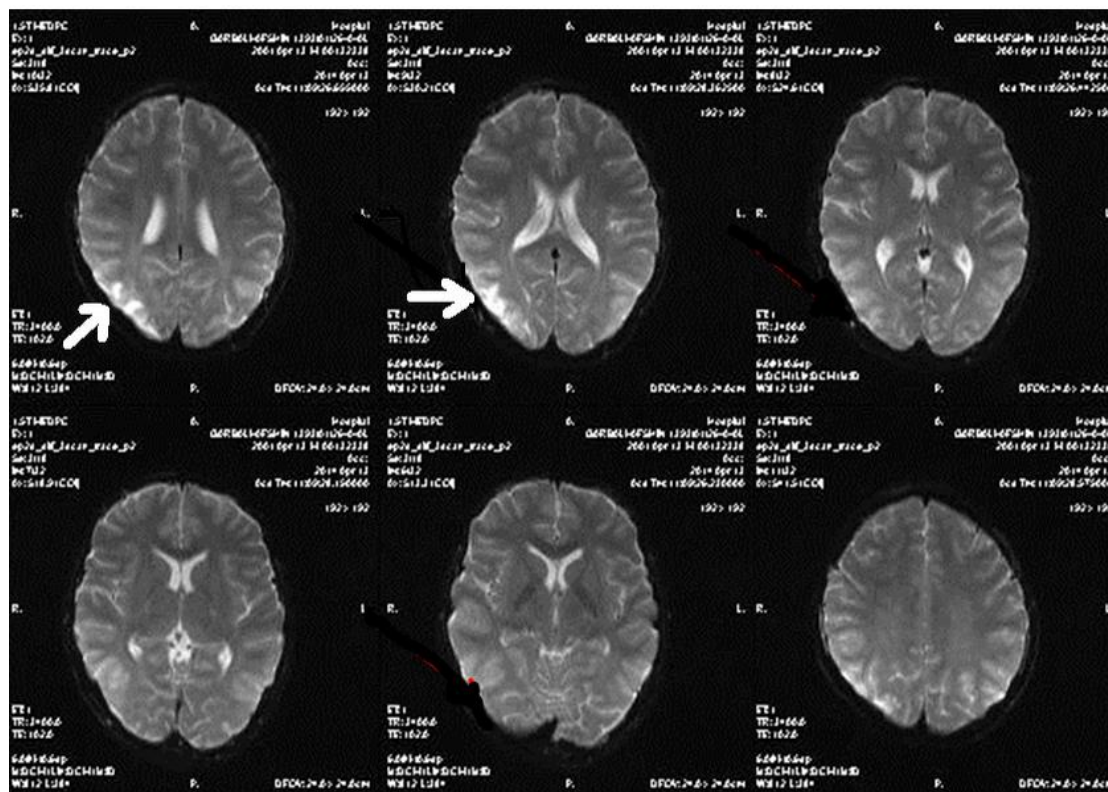


Figure 1. Hypersignal T2 area in both occipital regions

they were not detected in the presented boy. Hypotension and shock may result from a snake bite. The presence of rhabdomyolysis also reported frequently, which is documented with elevated creatine phosphokinase and detection of myoglobine in urine, which was not seen in studied patient. Renal function of this patient got better after 14 days and 2 weeks after discharge his kidney function was good. Neurotoxicity is another complication, characterized initially by ptosis, diplopia, and bulbar palsy and respiratory paralysis but in literature review we could not find PRES due to snake bite. PRES is a clinic-radiographic entity, which has similar findings on neuroimaging and symptom are headache, vision loss, altered mentation, and seizures.^{8,9}

The contributory factors were uncontrolled

References

1. Sitprija V, Sitprija S. Renal effects and injury induced by animal toxins. *Toxicon* 2012; 60(5): 943-53. Available from: <http://dx.doi.org/10.1016/j.toxicon.2012.06.012>
2. Gutierrez JM, Escalante T, Rucavado A. Experimental pathophysiology of systemic alterations induced by Bothrops asper snake venom. *Toxicon* 2009; 54(7): 976-87. Available from: <http://dx.doi.org/10.1016/j.toxicon.2009.01.039>
3. Pinho FM, Yu L, Burdmann EA. Snakebite-induced acute kidney injury in Latin America. *Semin Nephrol* 2008; 28(4): 354-62. Available from: <http://dx.doi.org/10.1016/j.semnephrol.2008.04.004>
4. Visweswaran RK, George J. Snake bite induced acute renal failure. *Ind J Nephrol* 1999; 9: 156-9.
5. Smith J, Greaves I. Crush injury and crush syndrome: a review. *J Trauma* 2003; 54(5 Suppl): S226-S230. Available from: <http://dx.doi.org/10.1097/01.TA.0000047203.00084.94>
6. Kalantri S, Singh A, Joshi R, Malamba S, Ho C, Ezoua J, et al. Clinical predictors of in-hospital mortality in patients with snake bite: a retrospective study from a rural hospital in central India. *Trop Med Int Health* 2006; 11(1): 22-30. Available from: <http://dx.doi.org/10.1111/j.1365-3156.2005.01535.x>
7. Kanjanabuch T, Sitprija V. Snakebite nephrotoxicity in Asia. *Semin Nephrol* 2008; 28(4): 363-72. Available from: <http://dx.doi.org/10.1016/j.semnephrol.2008.04.005>
8. Pedraza R, Marik PE, Varon J. Posterior reversible encephalopathy syndrome: a review. *Crit Care & Shock* 2009; 12: 135-43.
9. Stevens CJ, Heran MK. The many faces of posterior reversible encephalopathy syndrome. *Br J Radiol* 2012; 85(1020): 1566-75. Available from: <http://dx.doi.org/10.1259/bjr/25273221>
10. Bartynski WS. Posterior reversible encephalopathy syndrome, part 1: fundamental imaging and clinical features. *AJNR Am J Neuroradiol* 2008; 29(6): 1036-42. Available from: <http://dx.doi.org/10.3174/ajnr.A0928>

Conflict of Interests

Authors have no conflict of interest.

Acknowledgments

We kindly thank Dr. Banagozar, Dr. Ostadi and Dr. Ghaffari for their special comment.