



An Unusual Presentaton of Tuberculosis with Septic Shock and Immune Reconstitution Inflammatory Syndrome in an Immunocompetent Patient

**Suraj Patil ^{a≡}, K. Mayilananthi ^{a∅}, Durga Krishnan ^{a∅}, E. Dhivya ^{a*#}
and V. R. Mohan Rao ^{a†}**

^a Department of General Medicine, Chettinad Hospital and Research Institute, Chettinad Academy of Research and Education, Kelambakkam-603103, Tamil Nadu, India.

Authors' contributions

This work was carried out in collaboration among all authors. All authors read and approved the final manuscript.

Article Information

DOI: 10.9734/JPRI/2021/v33i57A33980

Open Peer Review History:

This journal follows the Advanced Open Peer Review policy. Identity of the Reviewers, Editor(s) and additional Reviewers, peer review comments, different versions of the manuscript, comments of the editors, etc are available here: <https://www.sdiarticle5.com/review-history/76625>

Case Study

Received 06 October 2021

Accepted 12 December 2021

Published 14 December 2021

ABSTRACT

Tuberculosis presenting as septic shock is a rare entity especially in an immunocompetent patient. It has been reported in only 1% of patients with septic shock. Tuberculosis associated immune reconstitution inflammatory syndrome (IRIS) is the paradoxical worsening of the current condition or the development of new lesions in patients who are on anti-tuberculosis treatment. In non-HIV patients with tuberculosis, the incidence of IRIS is only about 2.4%. We report a 29 year old immunocompetant female who presented with septic shock and on continued evaluation she tested positive for mycobacterium tuberculosis by Genexpert (sensitive to rifampicin) done in BAL fluid. All possible causes for immunodeficiency were ruled out. She was started on Anti-Tuberculosis therapy (ATT) and a month later, patient deteriorated clinically with high spiking temperatures and troublesome constitutional symptoms. Contrast-enhanced computed tomography (CECT) abdomen and chest revealed new onset multiple enlarged necrotic mediastinal, para aortic and hilar lymph nodes. After extensive evaluation including autoimmune profile, fungal culture, viral serology, Positron emission tomography (PET) scan, bone marrow analysis and ruling out all other possible

[≡]Post graduate;

[∅]Professor;

[#]Assistant Professor;

[†]Professor and Head;

*Corresponding author: E-mail: elangodhivya@gmail.com;

causes for fever, IRIS was suspected and patient was started on steroids along with ATT. There was a drastic improvement in her symptoms within a week. She completed her course of ATT and steroids were gradually tapered. At 2 years of follow up, the patient is doing well.

Keywords: Tuberculosis; septic shock, IRIS.

1. INTRODUCTION

Tuberculosis causing septic shock is extremely rare and has been identified in only 1% of patients with septic shock [1]. As tuberculosis is rarely considered as a differential diagnosis in patient with septic shock, there is undue delay in diagnosis. Prompt and timely administration of anti-tuberculosis drugs should cause recovery of septic shock in most of the individuals.

Immune reconstitution is the development of new lesions, clinical or radiological deterioration of preexisting lesions in a tuberculosis patient who show initial improvement on antituberculosis treatment [2]. Immune reconstitution inflammatory syndrome (IRIS) can occur within 2-4 weeks of starting anti-tuberculosis therapy and is more common in extrapulmonary TB. Immune reconstitution in non -HIV pulmonary tuberculosis patients is uncommon and has been reported in only 2.4% of patients till date [3]. There is no specific test for IRIS. Its diagnosis is based on excluding all other possible causes and response to steroids.

2. CASE REPORT

A 29 year old female presented with low grade fever once in every 2-3 days with evening rise, associated with nausea and vomiting for the past 4 months. For these symptoms she was not evaluated and on Over the Counter (OTC) medications. 5 days prior to admission, patient developed dry cough and breathing difficulty, for which she was admitted. There was a positive family history of pulmonary tuberculosis in her grandfather and younger sister. 2 days after admission, patient went in for respiratory distress and hypotension and was shifted to Intensive Care Unit (ICU). X-ray chest showed bilateral homogeneous opacities features suggestive of Adult respiratory distress syndrome (ARDS) (Fig.1). She was put on mechanical ventilation, and was on ionotropes for 3 days and gradually weaned off from both. She was treated with meropenem, colistin, linezolid as blood culture showed significant growth of *Staphylococcus epidermidis* and sputum culture revealed *Klebsiella pneumonia* growth. Laboratory

investigations are shown in Table -1. Infectious panel work up for leptospirosis, malaria, scrub typhus, H1N1, dengue, brucellosis and melioidosis was negative. Troponin I and Brain natriuretic peptide (BNP) were normal. Procalcitonin, antinuclear antibody (ANA) by immunofluorescence, antineutrophil cytoplasmic antibodies (ANCA), Anti-cyclic citrullinated peptides (anti-CCP) were negative. C-reactive protein (CRP) was 17 and d-dimer was 2284. High-resolution computed tomography (HRCT) chest done after stabilization showed subsegmental consolidation in anterior segment of both upper lobes (Fig.2). As she was unable to produce sputum, bronchoalveolar lavage was done. GENEXPERT revealed *Mycobacterium tuberculosis bacilli*, which was sensitive to rifampicin, so ATT was initiated. She was discharged after 20 days of hospital stay with a diagnosis of septicemia secondary to pulmonary tuberculosis with Adult respiratory distress syndrome (ARDS) and acute ischemic hepatitis.

After 4 weeks of starting ATT, patient again presented with high grade fever with chills, vomiting, cough with mucoid expectoration and abdominal pain in left hypochondrium. History of significant weight loss was also present without loss of appetite.

On examination, she was found to have pallor, tachycardia, high volume pulse, bilateral wheeze and crepitations over both lower zones and tender hepatosplenomegaly. Laboratory values are shown in table. She was non reactive for human immunodeficiency virus (HIV), Hepatitis B surface antigen (HBSAG) and hepatitis C virus (HCV). Infectious panel as well as autoimmune profile turned out to be negative again. CECT abdomen and chest revealed multiple enlarged necrotic mediastinal lymph nodes in prevascular, aortopulmonary and left hilar region, non specific atelectatic changes in medial segment of right middle and basal segment of lower lobe and mild splenomegaly with impression suggestive of TB (Fig. 3). Patient was thought to have drug resistant tuberculosis, so ATT was stepped up and levofloxacin was added without improvement in her symptoms.

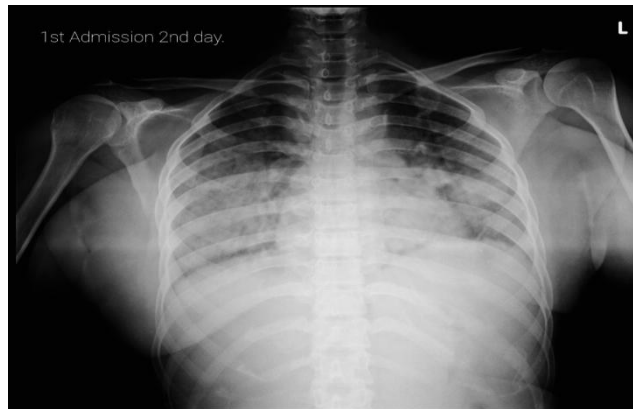

Fig. 1. Chest X-ray showing bilateral homogeneous opacities suggestive of Adult respiratory distress syndrome (ARDS)

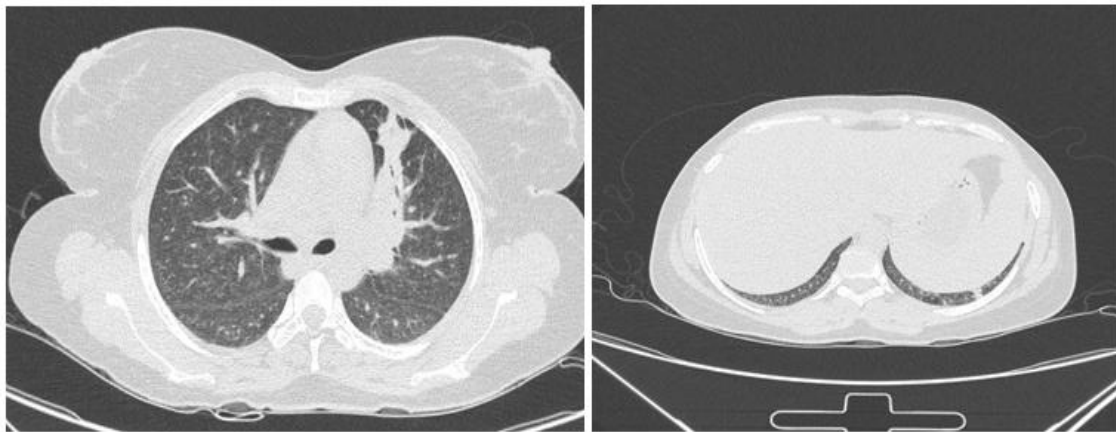


Fig. 2. High Resolution Computed Tomography CHEST shows subsegmental consolidation in anterior segment of both upper lobes and mild hepatosplenomegaly

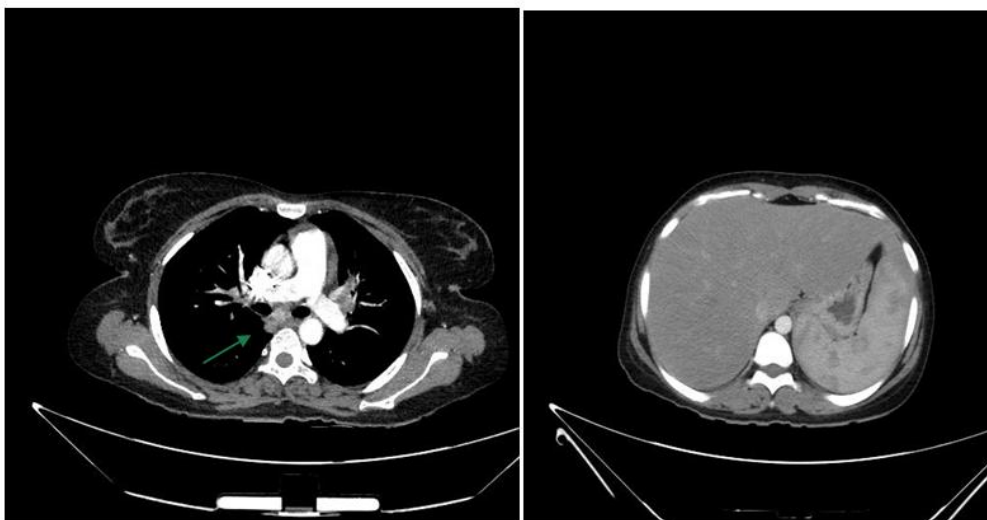


Fig. 3. Contrast Enhanced Computed Tomography chest and abdomen showing subcarinal lymph nodes enlargement with enhancement, with other lymph node enlargement and hepatosplenomegaly

After 15 days of hospital stay with frequent spikes of high grade fever, she developed dysphagia and chest pain. She was found to have tachycardia and hypotension and was shifted to ICU. Myocarditis was ruled out with enzymes and echocardiogram. As the possibility of malignancy was considered, Positron emission tomography (PET) scan was done which showed enlarged mediastinal lymphnodes with mild metabolic activity, hepatosplenomegaly with increased metabolic activity. Mild diffuse increased metabolic activity was noted in axial skeleton with no other abnormalities. Bone marrow aspiration and biopsy showed erythroid hyperplasia with megaloblastic change and no abnormal cells.

As infectious, autoimmune and malignancy were ruled out, the possibility of IRIS was considered. She was started on hydrocortisone with minimal improvement in her symptoms. So, hydrocortisone was replaced by oral prednisolone 40 mg per day and her fever subsided in 3 days. There was gradual improvement in general well being, cough, appetite and weight over a period of time. She was discharged after a month with a tapering course of steroids over 3 months. She completed the course of ATT and at 2 year follow up, the patient is asymptomatic.

3. DISCUSSION

Worldwide, tuberculosis is one of the leading causes of death especially in developing countries. In intensive care settings, tuberculosis is an important but poorly managed issue. Tuberculosis septicemia is extremely rare and has been recorded exclusively in

immunosuppressed patients especially in HIV. We report a young female who is immunocompetent, who developed an unusual complication of tuberculosis which is septic shock and furthermore developed IRIS on anti-tuberculosis treatment. Sepsis in mycobacterial disease is due to the release of tumor necrosis factor stimulated by lipoarabinomannan present in the tubercle bacilli. But in our patient even though the diagnosis was established early, there was a paradoxical worsening after initiation of treatment most likely due to immune reconstitution syndrome. Bosamiya et al also found out the paradoxical clinical worsening after the initiation of the anti-viral treatment [4]. In a patient with tuberculosis receiving appropriate treatment, if there is clinical deterioration then a paradoxical immune reaction to Mycobacterium tuberculosis must be suspected. In HIV infected patients with tuberculosis, IRIS has been reported in about 8-36% of patients, while in HIV negative patients with tuberculosis, the incidence is only about 2.4% [5]. Two types of TB-IRIS which have been described are paradoxical and unmasking forms. Both the forms are clinically indistinguishable from each other but paradoxical reactions are more common and well described. Paradoxical reactions are due to improved responsiveness of the hosts delayed hypersensitivity immunity due to the mycobacterial antigens released during the treatment. A high clinical suspicion is needed as it is predominantly a diagnosis of exclusion. Treatment consists mainly of steroids, non-steroidal anti-inflammatory drugs and careful observation. Steroid therapy has shown to rapidly improve the symptoms, reduce the hospitalization stay and has improved the quality of life significantly.

Table 1. Lab values during admission in index patient

Parameters	1 st admission				2 nd admission			
	D1	D3	D6	D14	D1	D7	D11	D15
BUN	7	5.4	13		3	2	3	4
Sr.Creatinine	0.61	0.68	0.54		0.38	0.51	0.69	0.83
PT	22.7	12.8			12.2	12.8		
INR	1.98	1.09			1.05	1.09		
Total protein	7.7	5.4	6.1	7.4	6.7	5.6	6.5	6
Albumin	3.6	2.6	3.4	3.4	3.1	2.4	2.9	2.4
Globulin	4.1	2.8	2.7	4.0	3.6	3.2	3.6	3.6
Bilirubin total	0.75	4.06	2.51	0.90	1.22	1.06	1.2	1.09
Bilirubin direct	0.18	3.88	1.58	0.48	0.4	0.8	0.82	0.88
AST	83	153	56	70	119	114	184	74
ALT	65	87	47	72	72	80	97	57
ALP	148	176	186	151	114	97	123	114
GGTP	122	127	93	128	75	54	81	95

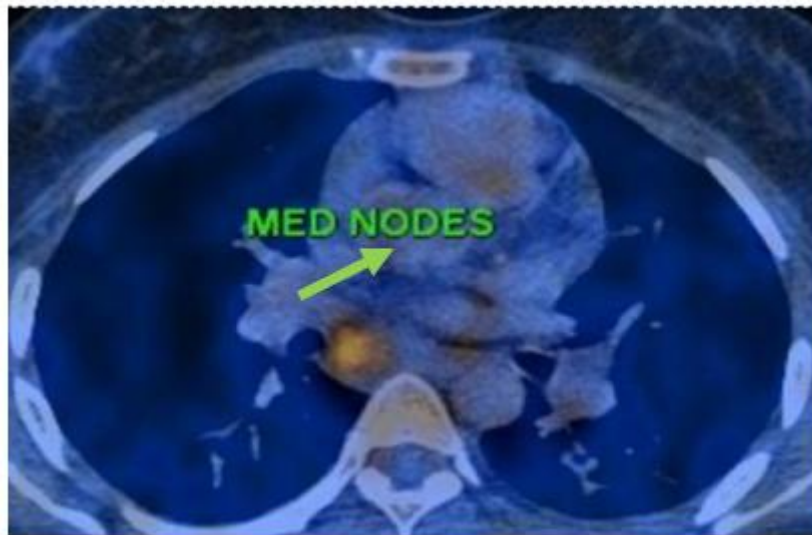


Fig. 4. Positron emission tomography (PET) showing enlarged mediastinal lymph nodes with mild metabolic activity

4. CONCLUSION

Tuberculosis septic shock can lead to a fatal outcome if there is a delay in diagnosis. Hence, a rapid diagnosis and prompt anti-tuberculosis treatment can prevent the associated morbidity and mortality. TB-IRIS should be suspected in a patient with clinical deterioration on initiation of chemotherapy and the diagnosis should be sought early to avoid untoward complications.

CONSENT AND ETHICAL APPROVAL

As per university standard guideline, participant consent and ethical approval have been collected and preserved by the authors.

COMPETING INTERESTS

Authors have declared that no competing interests exist.

REFERENCES

1. Kethireddy S, Light RB, Mirzanejad Y, Maki D, Arabi Y, Lapinsky S, Simon D, Kumar A, Parrillo JE, Kumar A Cooperative

- Antimicrobial Therapy of Septic Shock (CATSS) Database Group. Mycobacterium tuberculosis septic shock. *Chest*. 2013; 144:474–482.
2. Meintjes G, Lawn SD, Scano F, Maartens G, French MA, Worodria W, et al. Tuberculosis-associated immune reconstitution inflammatory syndrome: Case definitions for use in resource-limited settings. *Lancet Infect Dis*. 2008;8:516–23.
 3. Cheng SL, Wang HC, Yang PC. Paradoxical response during anti-tuberculosis treatment in HIV-negative patients with pulmonary tuberculosis. *Int J Tuberc Lung Dis*. 2007;11:1290–5.
 4. Bosamiya, Sanjay S. The immune reconstitution inflammatory syndrome. *Indian Journal of Dermatology*. 2011; 56(5):476-9. DOI:10.4103/0019-5154.87114.
 5. Novak RM, Richardson JT, Buchacz K, Chmiel JS, Durham MD, Palella FJ, et al. Immune reconstitution inflammatory syndrome: Incidence and implications for mortality. *AIDS*. 2012;26:721–30.

© 2021 Patil et al.; This is an Open Access article distributed under the terms of the Creative Commons Attribution License (<http://creativecommons.org/licenses/by/4.0>), which permits unrestricted use, distribution, and reproduction in any medium, provided the original work is properly cited.

Peer-review history:
The peer review history for this paper can be accessed here:
<https://www.sdiarticle5.com/review-history/76625>