



Experimental Periodontitis Does Not Influence the Peripheral Nerve Regeneration in *Wistar* Rats after Axonotmesis

**Jéssica Aline Malanotte¹, Lucinéia de Fatima Chasko Ribeiro²,
Ana Luiza Peretti¹, Rose Meire Costa Brancalhão²,
Gladson Ricardo Flor Bertolini², Patricia Oehlmeyer Nassar²
and Carlos Augusto Nassar^{2*}**

¹Graduate Program, Department of Biosciences and Health, State University of Western Paraná (UNIOESTE), Cascavel - Paraná, Brazil.

²State University of Western Paraná (UNIOESTE), Cascavel - Paraná, Brazil.

Authors' contributions

This work was carried out in collaboration between all authors. All authors read and approved the final manuscript.

Article Information

DOI: 10.9734/JAMMR/2018/45082

Editor(s):

(1) Dr. Mamta Kaushik, Professor, Department of Conservative Dentistry and Endodontics, Army College of Dental Sciences, India.

(2) Dr. Emad Tawfik Mahmoud Daif, Professor, Department of Oral & Maxillofacial Surgery, Cairo University, Egypt.

(3) Dr. James Anthony Giglio, Adjunct Clinical Professor, Oral and Maxillofacial Surgery, School of Dentistry, Virginia Commonwealth University, Virginia, USA.

Reviewers:

(1) Priscilla Farias Naiff, Universidade de Brasília, Brazil.

(2) Ilma Robo, Albanian University, Albania.

(3) Ghulam Hussain, Government College University, Pakistan.

Complete Peer review History: <http://www.sciencedomain.org/review-history/27801>

Original Research Article

Received 23 September 2018

Accepted 04 December 2018

Published 17 December 2018

ABSTRACT

Background and Objective: This paper aims at analysing the effect of the inflammatory periodontal disease condition on the peripheral nerve regeneration.

Methods: Thirty-two male rats were used and divided in 4 groups: control (CG); periodontitis (PG); nerve injury (IG); periodontitis with nerve injury (IPG). On the first experiment, the animals were submitted to a bilateral ligature around the lower first molars. Then, on the fifteenth day, they were submitted to a peripheral nerve injury and euthanised on the thirtieth day, then, their sciatic nerve and their right hemimandibles were collected.

*Corresponding author: E-mail: canassar@yahoo.com;

Results: The induction of the periodontitis was proved by the histomorphometric of the mandible. When it comes to the nerve morphometric analysis, there was no difference among the nerve fibers groups (NF) compared to the viable FN longer than 4 micrometers (μm), CG and PG presented higher quantity of IG and IPG, on the less than 4 μm fibers, being similar in these groups. CG and PG presented smaller quantity of nonviable fibers. The NF diameter, axon and myelin sheath, CG and PG presented diameters longer than 4 μm , while only the MS presented shorter than 4 μm difference, CG presented a longer diameter than IG and IPG. All groups depicted similar quantities of blood vessels, conjunctive tissue and cell nuclei density, CG and PG presented lower values than the other groups.

Conclusion: Therefore, it can be suggest that induced periodontitis did not influence the sciatic nerve process of regeneration.

Keywords: Periodontitis; inflammation; sciatic nerve; nerve crush; nerve regeneration.

1. INTRODUCTION

The periodontitis is responsible for destroying the supportive tissue of the teeth, as it stimulates an unbalance condition on the buccal region, promoting the growth of bacteria and bacterial plaque as well as triggering local and systemic inflammation [1].

This systemic inflammation is originated by pro-inflammatory cytokines released at the periodontal infection spot, which infiltrates on the blood system and reach other places, being, that way, related to the increase of systemic changes, such as cardiovascular diseases, cerebrovascular, atherosclerosis and Alzheimer's disease [2,3]. The action mechanisms, though, are still not yet clarified [4].

Another known inflammatory condition is the peripheric nerve injury (PNI), which is common and can decrease the patient's life quality, resulting in impairments in the long-term. When the injuries cause damages only on the axons and their myelin sheath, they are characterised as a second level injury, axonotmesis type, without any damage to the epineurium, being mechanical traumas the most common cause [5-7].

After the injury, a series of molecular and cellular change occur in the nerve, characterising the Wallerian degeneration, in which the axon and the myelin sheath (MS) suffers degeneration [8], leading to a macrophagic influx and Schwann cells proliferation, responsible for the removal of these structures, creating a local inflammatory response due to the increase of pro-inflammatory cytokines expression, as a factor of alpha tumor necrosis (TNF- α), interleukin 1 β (IL1 β) and (IL6) [9,10].

When this stage is accomplished, the Schwann cells align themselves forming a band of

Bungners [11], mainly source of neurotrophic factors, relevant to the axon regeneration [7], however, the complete recovery is not very common, as it can be misdirected or associated with neuropathic debilitating pain, often triggering a responsive inflammatory chronic reaction in this tissue [12].

Gurav [3] proposed a possible periodontitis association with the nerve injury, in which the periodontitis through a systemic inflammation, would be responsible for the exacerbation of the neuro degeneration, serving as a source of pro-inflammatory systemic factors, capable of effecting the vascular integrity of the brain and which could perpetuate the chronic inflammatory process by the activation of an innate immune response. Although the mechanism between the relation between the periodontitis and the decrease of the cognitive Alzheimer's disease is not clear yet, there is increased evidences to support the role of the systemic disease evolution.

This way, this study aimed at analysing the effect of the inflammatory condition of the periodontal disease upon the experimentally induced peripheric nerve regeneration.

2. MATERIALS AND METHODS

The research was carried at the Injury and Physical Therapy Resources Study Laboratory (LELRF) in partnership with the Structural and Functional Biology Laboratory of the Western State University of Parana (UNIOESTE). All experimental procedures were submitted and approved by the Ethical Committee of Animal Use of UNIOESTE(certificate number 07/18 - CEUA - UNIOESTE).

2.1 Sample Group

Thirty-two males *Wista* rats were used, 8 weeks old, weighting an average 250g, from the

UNIOESTE central vivarium. The animals remained at the sectorial vivarium of LELRF, under controlled conditions of temperature ($23 \pm 2^\circ \text{C}$) and light (cycle of light-dark-of 12 hours), they received water and commercial rat food at all times. The animals were distributed randomly in 4 groups of 8 animals in each:

- Control Group (CG), did not suffer intervention;
- Periodontitis Group (PG), submitted to the induction of periodontitis experimental procedure by ligature on the first day of the experiment;
- Nerve Injury Group (IG), submitted to a nerve injury after the fifteenth day of the experiment;
- Periodontitis with Nerve Injury Group (IPG), submitted to a periodontitis experimental induction by ligature and nerve injury;

All animals were euthanised after the thirtieth day of the experiment.

2.2 Induction of Periodontal Disease Protocol / Experimental Periodontitis

On the experiment's first day, the animals of the group PG and IPG weighted and anaesthetised with ketamine (100 mg/Kg), xylazine (50 mg/Kg) (Sespo Industry and Trade Ltda, São Paulo, Brazil), by *via* intraperitoneal, placed on the appropriate operatory table, which allowed easier access upon the teeth on the posterior jaw region. With the support of a modified pinch and an explorer probe, cotton ligatures number 40 were placed around the lower right and left first molar. This ligature acted irritating the gingival margin for 30 days, provoking the accumulation of bacterial plaque and, consequently, the development of the periodontal disease [13].

2.3 Compression Injury of the Sciatic Nerve Experimental Model

On the experiment's 15th day, previous to the surgery procedure of compression injury of the sciatic nerve, the IG and IPG group were weighted and anaesthetised. A trichotomy was carried on the posterior region of the left thigh and, after, with the support of scalpel, and incision parallel to the fibers of the biceps femoral muscle was done to expose the sciatic nerve and, consequently, its compression with a haemostatic pinch, for 30 seconds. The pressure

of the pinch was the same in all animals, having as a reference the second rack's teeth, all of them done by the same person, with anepineural suture placed as a mark in the injured spot [14,15].

2.4 Animal Euthanasia

On the experiment's last day (30th), all animals were weighted and anaesthetised, a dissection done, followed by the removal of 2 cm of the sciatic nerve, distal to the compression procedures, for a morphological nerve tissue analysis. Soon after, the animals were euthanised by guillotine decapitation and their right hemimandibles collected for posterior histomorphometric analysis.

2.5 Mandible Histomorphometric Analysis

After the animals' euthanasia, the right hemimandibles side were collected, dissected and fixed in a solution of 10% formaldehyde, for 24 hours. After this period, distilled water was used to wash them and trichloroacetic acid (TCA) of 5% was used to decalcify for about 14 days. The samples were dehydrated for 1 hour and half in alcohol 70%, 80%, and 90% and overnight alcohol 95%. Next day, they were put on alcohol 100% in 4 baths of an hour each.

After that, the material was diaphanised, impregnated and included in paraffin. Later on, microtomy was done, with $7\mu\text{m}$ cuts in a microtome (*Hestion*®, *ERM3000*, *Daintree Scientific*, St. Helens, Australia) and the slides colored with hematoxylin and eosin.

The measurement of the alveolar bone crest was done through a microscope attached to a computer, which permitted capture images, through the *software LazEz*®. A measurement of the shorter distance between the top of the buccal alveolar crest and the cementum-enamel junction was done using an analysing program of images *Image Pro-plus* 6.0 software. The measurements were repeated once a day, in three different days, and then an average of the values was done [16].

2.6 Sciatic Nerve Histomorphometric Analysis

The first fragment collected near the nerve injury was put in paraformaldehyde 7% in PBS (pH 7,4), for 24 hours and, then, placed in glycine and after fixed in osmium tetroxide 2% in PBS,

dehydrated, diaphanised, infiltrated and put in blocks of histological paraffin to obtain the transverse cuts of the nerve with a thickness of 5 µm [17]. Later on, the histological slides were assembled, with 100x objective microphotography (4 fields), and analysed through the *Image Pro-plus* 6.0 software.

The collected images were analysed according to following parameters: total number of nerve fibers, total number of viable fibers and total number of nonviable fibers (the ones that did not present definite layout permitting measurement) axon diameter, nerve fiber diameter and myelin sheath thickness (given by the axon diameter minus the nerve fiber, divided by 2).

Aiming at distinguishing the nerve fibers with longer or shorter diameters, we used as a basis Mazzer et al. [18] and Livnat et al. [19] studies, which described the distinction of the longer and shorter fibers injury on the sciatic nerve, the reference of measure being 4 µm for an analysis of the nerve fiber, higher or equal to 4µm were considered longer diameter and fibers with less than 4 µm. Four pictures of each cut were taken, regarding of each part of the image, right and left superior quadrant, right and left inferior quadrant, on the 100x objective. The analysis was done in a blind way when it comes to the groups, 25 fibers of higher diameters were measured and 25 of lower diameter per quadrant, totalising 200 fibers per nerve, or even in its totality, when it did not reach the number of fibers.

The second distal nerve injury fragment was fixed in paraformaldehyde 7% for 24 hours, following the histological routine procedure for the inclusion in histological paraffin and then cut transversally with 5µm thickness. After that, colored with hematoxylin and eosin and microphotographed in four fields, with the 100x objective, aiming at counting the cell nuclei and blood vessels in the *Image Pro-plus* 6.0 software. The exclusion borders were included in the numbers, the analysed object that touched the superior left borders, while the exclusion border was the right inferior one. The conjunctive tissue was quantified through Masson Trichrome coloring through counting the pixels using a rule of three, given by the quantity of conjunctive tissue divided by the quantity of pixels in the image, in the *Image Pro-plus* 6.0.

2.7 Data Analysis

The results were expressed and analysed through a descriptive and inferential statistics

analysis. Firstly, they were evaluated by its normality according to the Shapiro-Wilk test and, as they presented normal distribution, the Anova unidirectional test was used, followed by the Tukey test when there was a significant difference. The variable numbers were analysed through the BioEstat 5.0 test. We considered it significant when $p < 0.05$.

3. RESULTS

3.1 Measuring the Distance between the Alveolar Bone Crest to the Lower First Molar Cementum-enamel Junction

By the measurement of the distance between the alveolar bone crest to the lower first molar cementum-enamel junction, we could verify that there was a loss of supportive tissue from the animals exposed to the experimental periodontal disease ($p < 0,05$), showing effectivity regarding the induction of the periodontal disease on the alveolar bone tissue (Table 1).

Table 1. Measuring the distance between the alveolar bone crest until the lower first molar cementum-enamel junction

Group	Average (pixels)
CG	17.18 ± 3.47 A
PG	34.38 ± 9.73 B
IG	17.08 ± 3.56 A
IPG	34.59 ± 9.68 B

CG, control group; PG, periodontitis group; IG, nerve injury group; IPG, periodontitis group with nerve injury. Different letters indicate significant statistic difference. Values represent an average ± standard deviation.

3.2 Nerve Fibers Total, Viable and Nonviable Nerve Fibers

In regards of total number of nerve fibers, there was no statistic significant difference among the groups ($p = 0,625$). For the quantity of nonviable nerve fibers of the CG and PG groups, they present similar behaviors, when it comes to the groups that had a peripheric nerve injury, IG and IPG, they showed an increase on the number of nonviable fibers ($p < 0,05$), (Image 1A). The total number of longer than 4 µm viable nerve fibers, the CG and PG presented similar results, the groups that had the peripheric nerve injury showed a decrease on the total number of viable fibers ($p < 0,05$). For fibers shorter than 4 µm, the PG presented the lowest quantity number of viable fibers than the CG and IPG ($p < 0,05$), (Image1B).

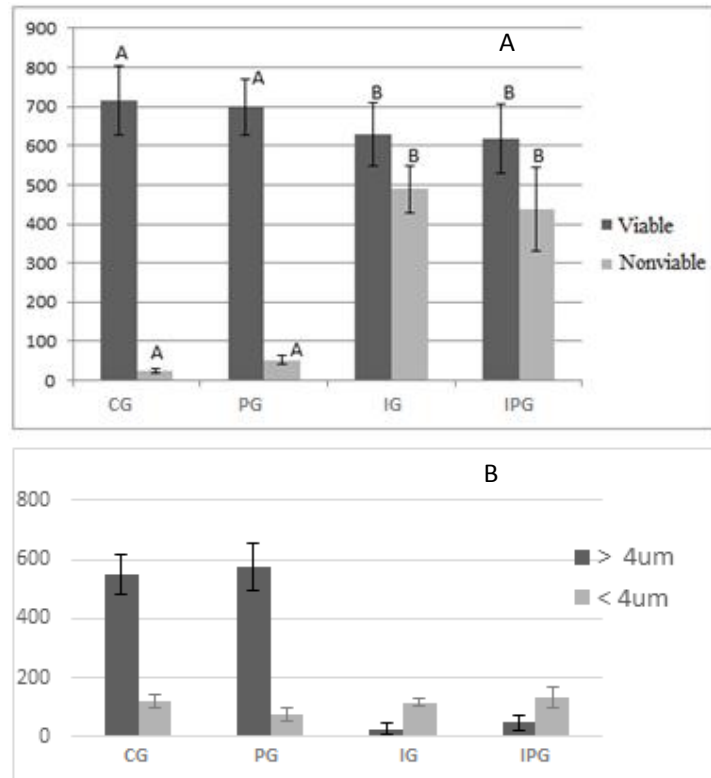


Image 1. A- Nerve fibers total viable and nonviable. B- Nerve fibers total viable, fibers total longer and shorter than 4 micrometers. CG, control group; PG, periodontitis group; IG, nerve injury group

IPG, periodontitis disease group with nerve injury. Different letters indicate significant statistic difference. Values represent an means ± standard deviation (units).

3.3 Nerve Fibers Diameter

On the analysis of the longer than 4 μm nerve fibers diameter, CG and PG presented similar results, while the other groups that had the peripheral nerve injury showing a decrease on the fiber never diameter (p<0,05). For shorter than 4 μm fibers, there was no difference among the groups (p=0.219) (Table 2).

Table 2. Nerve fibers diameter, longer and shorter than 4 micrometers

Group	> 4 μm(μm)	< 4 μm(μm)
CG	86.95 ± 0.68 A	29.44 ± 0.17 A
PG	88.65 ± 0.70 A	29.18 ± 0.25 A
IG	44.77 ± 0.09 B	30.86 ± 0.11 A
IPG	45.20 ± 0.23 B	30.62 ± 0.30 A

CG, control group; PG, periodontitis group; IG, nerve injury group; IPG, periodontitis group with nerve injury, μm – micrometers, > - longer, < - shorter. Different letters indicate significant statistic difference. Values represent an average ± standard deviation.

3.4 Axon Diameter

Regarding the axon shorter than 4 μm diameter fiber diameter, CG and PG presented equivalent results, while the groups that had peripheral nerve injury showed a decrease on the axon diameter (p<0,05). For shorter than 4 μm fibers, the CG presented a shorter value than the other groups (p<0,05), (Table 3).

3.5 Myelin Sheath Thickness

For longer than 4 μm fibers, the CG and PG presented similar results, the other groups who had the peripheral nerve injury showed a decrease on the number of myelin sheath thickness (p<0,05). While the other shorter than 4 μm fibers, CG presented a higher number of thickness than the groups with peripheral nerve injury (p<0,05), (Table 3).

Table 3. Axon diameter, longer and shorter than 4 micrometers. Myelin Sheath Thickness of fibers longer and shorter than 4 micrometers

Group	Axon (μm)		Myelin Sheath Thickness(μm)	
	> 4 μm	< 4 μm	> 4 μm	< 4 μm
CG	42.23 \pm 0.18 A	14.08 \pm 0.16 A	1.60 \pm 0.54 A	0.77 \pm 0.06 A
PG	45.46 \pm 0.26 A	17.25 \pm 0.12 B	1.80 \pm 0.44 A	0.67 \pm 0.04 AB
IG	26.07 \pm 0.20 B	18.28 \pm 0.12 B	0.93 \pm 0.06 B	0.62 \pm 0.02 B
IPG	26.66 \pm 0.23 B	19.14 \pm 0.14 B	0.92 \pm 0.10 B	0.65 \pm 0.06 B

CG, control group; PG, periodontitis group; IG, nerve injury group; IPG, periodontitis group with nerve injury, μm – micrometers, > - longer, < - shorter. Different letters indicate significant statistic difference. Values represent an average \pm standard deviation.

Table 4. Quantifying the blood vessels, cell nuclei and conjunctive tissue percentage

Group	Blood vessels (n)	Cell nuclei (n)	Conjunctive tissue (%)
CG	14.0 \pm 5.33 A	115.6 \pm 20.9 A	2.38 \pm 0.27 A
PG	9.4 \pm 0.89 A	109.8 \pm 15.1 A	2.22 \pm 0.25 A
IG	15.0 \pm 4.35 A	431.6 \pm 88.9 B	3.25 \pm 0.21 B
IPG	15.8 \pm 10.63 A	319.4 \pm 75.0 C	3.54 \pm 0.45 B

CG, control group; PG, periodontitis group; IG, nerve injury group; IPG, periodontitis group with nerve injury. Different letters indicate significant statistic difference. Values represent an average \pm standard deviation

3.6 Quantifying the Blood Vessels, Cell Nuclei and Conjunctive Tissue Percentage

There was no significant statistic difference on the blood cells analysis among the groups ($p=0,41$). Regarding the cell nuclei, CG and PG presented similar behaviors; the groups submitted to the peripheric nerve injury presented higher cell nuclei cell density ($p<0,05$). Besides that, the IPG presented a smaller value in relation to the IG ($p<0,05$). The results of the conjunctive tissue were equivalent for the CG and PG, the groups submitted to the peripheric nerve injury presented a higher conjunctive tissue percentage ($p<0,05$), (Table 4).

4. DISCUSSION

Up until this moment, we could not find studies that would associate PNI with periodontitis, this way our research aimed at evaluating the effects of these two conditions associations, once the periodontitis is a disease of inflammatory characteristics. Other studies, however, have increasingly related the periodontitis as a risk factor for the development of systemic diseases, through the inflammation of its pathogenic agents would result in reaching the blood circulation of the affected individuals [4,20,21].

The sciatic nerve is formed of long nerve fibers, which originates from the lumbosacral plexus responsible for the motor and sensory characteristic of the lower limbs innervation. Due to its long extension, traumas and ischemia, it can cause relatively common damages, causing inferior members disfunctions [7]. This way, the study of the peripheral nerve injury, several authors chosen for experimental compression injury models, classified by Seddon [22] an axonotmesis, that involves direct damages to the axon besides the focal de-myelinisation, preserving the supporting structures and maintaining the epineurium continuity, which has the function of guiding the new axon to the regeneration of the target-organ [23].

In this current study, conducted for 37 days, 15 days after the experimental axonotmesis, it was possible to observe that all the groups presented a similar average in relation to the total number of fibers present in the sciatic, differing only in the number of viable and nonviable fibers, that being the CG and PG presented a higher number of viable fibers, while the nonviable fiber values were lower compared to the IG and IPG (Image 1A and 1B), these presented a higher number of nonviable fibers pointing at the studies of Antunes et al. [14] when depicting that the PNI was responsible for structural changes in these nerve fibers.

There was no reduction on the total nerve fibers in those injured groups, however, the nerve structures were shorter and thinner than the others, that means, in the IG and IPG there was a significant increase on number of fibers shorter than 4 μm (Table 2), showing a possible nerve regeneration, supporting the studies of Sta et al. [24], which pointed at the recent regenerated axon presented a smaller diameter than the survival axon and yet not myelinated, explaining, then, the higher number of viable fibers in shorter than 4 μm diameters in these groups.

According to Svennigsen and Dahlin [25], deficiencies (MMP) 9 and 2 in special, harmed the re-myelinisation interfering in the intranodal length and the regenerations of the Ranvier nodes, which could be suppressed by the systematic effects provoked by the established periodontal disease, which could cause an increase on the release of MMPs, after the inflammatory stimulus, among other actions taken to a destruction of local tissue that supports the teeth [26]. Still in accordance with Toregeani et al. [26], the periodontitis increases the release and the production of pro-inflammatory factors as the prostaglandins, MMPs, IL 1 beta, IL6, TNF alfa and C-reactive protein and it decreases the IL10 and IL4 which are anti-inflammatory cytokines [27], those act on the nerve regeneration, which means that the most elevated levels of circulating inflammatory biomarkers could play a role on the systemic disease contribution⁴. Our study, however, could not have been carried out without this action once that even on the IPG group presenting low numbers of viable fibers and more quantity of viable fibers in comparison with the IG, there was no statistic significant difference between them, those inflammatory characteristics, therefore, systematically triggered by the PD did not present sufficient factors to positively interfere, but, on the other hand, they also did not play any negative role on the nerve regeneration.

The local inflammation on the PNI, consequently, is responsible for a series of histopathological events associated with morphological and functional changes, triggering the nerve degeneration and, soon after, the cleansing of myelinic and axon detritus, contributing for an environment of regeneration [8], besides, this also results in the reorganisation and proliferation of Schwann cells, responsible for the neurotrophic factors of the axon growth [10]. This way, the systemic inflammation could be a factor to aggravate the local inflammation turning it into a dysfunction and increase on the local

inflammatory process, making the nerve fiber degeneration worse, even though this change was not observed in our study.

When it comes to the diameter of the nerve fiber, the axon and the myelin sheath, longer than 4 μm fibers, the CG and PG presented better results than the groups that were submitted to the PNI, highlighting that at the changes that may occur in their structures due to the PNI, where a decrease on these three structures occurs, also stated at the Antunes et al. [14] studies, in which they observed their presence on thinner structures, indicating that it would be take a longer study time to register the significant data related to these structures' diameter.

On shorter than 4 μm fibers, there was no statistic significant difference on the nerve fiber's diameter, while the axon diameter and the CG presented a shorter average than the others, pointing at an increase of these axons on groups submitted to PNI, which could be justified by the nerve regeneration that is taking place on these groups. Although the IPG was not significant, it presented a thicker MS than the IG, which could suggest the hypothesis that the periodontitis could have played a sensitising effect on the MS regeneration, probably due to the release of MMP effect in systemic level, acting on the regeneration of this structure [25].

When we compared the CG and the PG with the groups submitted to the nerve injury, it was possible to observe the lower values of MS, showing that the re-myelinisation was not yet totally present in these groups, result also found on the Sta et al. [24] study, where they analysed the electrophysiologic, behavior and morphologic parameters relation to the sciatic nerve in rats after the compression injury. They observed that the first signs of myelinisation started after the 21st post-surgery day, highlighting that it would possibly require a longer time to study, register significant data, as this study could only be carried out up until the 15th peripheral nerve injury post-surgery day, not being possible to observe the complete de re-myelinisation signs.

Analysing the blood vessels, we did not find statistic differences among the groups, it is known, however, that, after the nerve injury, angiogenesis occurs [28]. Relevant aspect, this fact points at the vessels injuries after the nerve injury, forming an endoneurial hematoma, and consequently ischemia, which can harm the nerve regeneration due to the lack of nutrients

and support for the removal of the myelin and what was left of the axons [29]. It could have been, this way, in our study, a factor to harm the nerve regeneration as it did not observe an increase on the blood vessels quantity after the LNP.

When it comes to the cells nuclei analysis and the conjunctive tissue percentage, the IG and IPDG showed higher values, that means, the PNI increases the number of the cell nuclei and the conjunctive tissue percentage. During the process of regeneration, the nerve fibers need to be restored quickly, before the bungner bands are closed, otherwise, a scar tissue occur in an inaccessible new innervation area [30], which could have happened to the groups submitted to the PNI, justifying the increase on the cells nuclei due to the fibroblasts presence, resulting on a high number of endoneurial tissue. Apart from that, the inflammatory and Schawnn cells can be present, as after 15 days after the injury, it is still on the regeneration phase, that could occur about 7 to 28 days after the injury [24], phase characterised by the increase of these cells which will align and be responsible for the bungersbands formation, resulting in an environment rich in trophic factors, permitting an axonal regeneration and directing them to the distal stump [6].

Proving the efficiency of the experimental periodontitis model, the mandibles measurement made it possible to observe the distance between the alveolar crest until the animals' lower first molar cementum-enamel junction, showing the effectiveness of the technique to induct the periodontal disease by ligature, resulting on the absorption of bone tissue. These findings are in accordance with the Nassar et al. [13], studies that put these characteristics as signs of periodontitis occurrence.

According to Toregeani et al. [26], the development of periodontitis, after the inflammatory stimulus, an increase of the prostaglandins e2 and MMP occur, which leads to the extracellular gingival destruction and of the periodontal ligature, stimulating the reabsorption of the alveolar bone. The effect of the MMPs release and the bacterial proliferation are the activation of several cells such as fibroblasts, keratinocytes, macrophages and endothelial cells, responsible for the bone reabsorption through the element fragmentation of the extracellular osteoclasts matrix.

5. CONCLUSION

Therefore, up until it was possible to study, it can be conclude that the experimentally induced periodontal disease did not influence on the regeneration process of the nerve tissue after the induction of a peripheric nerve injury.

CONSENT

It is not applicable.

ETHICAL APPROVAL

All experimental procedures were submitted and approved by the Ethical Committee of Animal Use of UNIOESTE(certificate number 07/18 - CEUA - UNIOESTE).

COMPETING INTERESTS

Authors have declared that no competing interests exist.

REFERENCES

1. Vyeira RC, Rosales C, Querol EU. Neutrophil functions in periodontal homeostasis. *J Immunol Res.* 2016;16:1-9.
2. Hosomi N, Aoki S, K Matsuo K, Deguchi K, Masugata H, Murao K, Ichihara N, Ohyama H, Dobashi H, Nezu T, Ohtsuki T, Yasuda O, Soejima H, Ogawa H, Izumi Y, Kohno M, Tanaka J ,Matsumoto M. Association of serum anti-periodontal pathogen antibody with ischemic stroke. *Cerebrovasc Dis.* 2012;34:385–392.
3. Gurav AN. Alzheimer's disease and periodontitis – an elusive link. *RAMB.* 2014;60:173-180.
4. Nagpal R, Yamashiro Y, Izumi Y. The two-way association of periodontal infection with systemic disorders: An overview. *Mediators Inflamm.* 2015;15:1-9.
5. Bastien D, Lacroix S. Cytokine pathways regulating glial and leukocyte function after spinal cord and peripheral nerve injury. *Exp Neurol.* 2014;258:62–77.
6. Faroni A, Mobasser A, Kingham PJ, Reid AJ. Peripheral nerve regeneration: Experimental strategies and future perspectives. *Adv Drug Deliv Rev.* 2015;82:160–167.
7. Menorca RMG, Fussel TS, Elfar JC. Peripheral nerve trauma: Mechanisms of

- injury and recovery. *Hand Clin.* 2013;29: 317–330.
8. Gu X, Ding F, Williams DF. Neural tissue engineering options for peripheral nerve regeneration. *Biomaterials.* 2014;35:6143-6156.
 9. Bombeiro AL, Santini JC, Thomé R, Ferreira ERL, Nunes SLO, Moreira BM, Bonet IJM, Sartori CR, Verinaud L, Oliveira ALR. Enhanced immune response in immunodeficient mice improves peripheral nerve regeneration following axotomy. *Front Cell Neurosci.* 2016;10:1-14.
 10. Stratton JA, Shah PT. Macrophage polarization in nerve injury: Do Schwann cells play a role? *NRR.* 2016;11:53-57.
 11. Scheib J, Hoke A. Advances in peripheral nerve regeneration. *Nat Rev Neurol.* 2013; 12:668-676.
 12. Houschyar KS, Momeni A, Pyles MN, Cha JY, Maan N, Duscher D, Jew OS, Siemers F, Schoonhoven JV. The Role of current techniques and concepts in peripheral nerve repair. *PlastSurg Int.* 2016;16:1-8.
 13. Nassar PO, Nassar CA, Guimarães MR, Aquino SG, Andia DC, Muscara MN, Spolidorio DM, RossaCJr, Spolidorio LC. Simvastatin therapy in cyclosporine A-induced alveolar bone loss in rats. *J Periodontal Res.* 2009;44:479-488.
 14. Antunes JS, Lovison K, Karvat J, Peretti A L, Vieira L, Higuchi GH, Brancalhão R MC, Ribeiro LFC, Bertolini GRF. Nociceptive and neuronal evaluation of the sciatic nerve of wistar rats subjected to compression injury and treated with resistive exercise. *Pain Res Manag.* 2016; 16:1-7.
 15. Bridge PM, Ball DJ, Mackinnon SE, Nakao Y, Brandt K, Hunter D A. Nerve crush injuries – A model for axonotmesis. *Exp Neurol.* 1994;127:284-290.
 16. Boamorte CC, Pasqualotto LF, Brancalhão RMC, Ribeiro LFC, Nassar PO, Schneider SCS, Nassar CA. Assessing the action of phytoestrogens on alveolar bone tissue of female of ovariectomized rats with induced periodontal disease. *Am Int J Contemp Res.* 2016;6:166-178.
 17. Di Scipio F, Raimondo S, Tos P, Geuna S. A simple protocol for paraffin-embedded myelin sheath staining with osmium tetroxide for light microscope observation. *Microsc Res Tech.* 2008;71: 497-502.
 18. Mazzer PYCN, Barbieri CH, Mazzer N, Fazan VPS (2006) Qualitative and quantitative evaluation of acute injuries by smashing rat ischiatic nerve. *Acta Ortop Bras.* 2006;14:220-225. (*in Portuguese*)
 19. Livnat MMM, Almog M, Nissan M, Loeb E, Shapira Y, Rochkind S. Photobiomodulation triple treatment in peripheral nerve injury: nerve and muscle response. *Photomed Laser Surg.* 2016; 34:638-645.
 20. Ide M, Harris M, Stevens A, Sussams R, Hopkins V, Culliford D, Fuller J, Ibbett P, Raybould R, Thomas R, Iqbal PS, Nubesh Khan SN, Haris M, Narayanan M, Laju S, Kumar SS. Assessment of systemic inflammatory markers in patients with aggressive periodontitis. *J Int Oral Health.* 2015;7:48-51.
 21. Leite MA, Mattia TM, Kakahata CMM, Bortolini BM, Rodrigues PHC, Bertolini G RF, Brancalhão RMC, Ribeiro LFC, Nassar CA, Nassar PO. O. Experimental periodontitis in the potentialization of the effects of immobilism in the skeletal striated muscle. *Inflam.* 2017;40:2000-2011.
 22. Seddon HJ, Medawar PB, Smith H. Rate of regeneration of peripheral nerves in man. *J. Physiol.* 1943;102:191-215.
 23. Rosa-Junior GM, Magalhães RMG, Rosa VC, Bueno CRS, SimionatoLH, Bortoluci CH. Effect of the association of laser therapy with swimming in the morphological repair of the sciatic nerve and in the functional recovery of rats submitted to axonotmesis. *RPF.* 2016;23: 12-20. (*in Portuguese*)
 24. Sta M, Cappaert NLM, Ramekers D, Baas F, Wadmanb WJ. The functional and morphological characteristics of sciatic nerve degeneration and regeneration after crush injury in rats. *J Neurosci Methods.* 2014;222:189-198.
 25. Svennigsen AF, Dahlin LB. Repair of the peripheral Nerve - remyelination that works. *Brain Sciences.* 2013;3:1182-1197.
 26. Toregeani JF, Nassar CA, Toregeani KAM, Nassar PO. Periodontal diseases and atherosclerosis. *J Vasc Bras.* 2014;13: 208-216. (*in Portuguese*)
 27. Mootha A, Malaiappan S, Javakumar ND, Varghese SS, Thomas JT. The effect of periodontitis on expression of interleukin-

- 21: A systematic review. *Int J Inflam*. 2016;16:1-8.
28. Terra R, Silva SAG, Pinto VS, Sutra PML. Effect of exercise on the immune system: response, adaptation and cell signaling. *RBME*. 2012;18:208-214.
29. Kakahata CMM, Malanotte JA, Karvat J, Brancalhão RMC, Ribeiro LFC, Bertolini GRF. The morphological and functional effects of exercise in the aquatic environment, performed before and/or after sciatic nerve compression in Wistar rats. *JER*. 2016;12:393-400.
30. Krueger-Beck E, Scheeren EM, Nogueira GN, Nohama P. Electric and magnetic fields applied to peripheral nerve regeneration. *Rev Neurociênc*. 2011;19: 314-328.

© 2018 Malanotte et al.; This is an Open Access article distributed under the terms of the Creative Commons Attribution License (<http://creativecommons.org/licenses/by/4.0>), which permits unrestricted use, distribution, and reproduction in any medium, provided the original work is properly cited.

Peer-review history:

The peer review history for this paper can be accessed here:
<http://www.sciencedomain.org/review-history/27801>