

Ultrasound-Guided Peribulbar Block with Blunt Canula for Cataract Surgery: A Review of Historical Case-Series

Hugo C. T. Siqueira^{1*}, Clarissa M. M. Stoffel De Siqueira²,
Marlon Miguel Bianchi De Lima², Leonardo T. C. Lins³

¹Department of Anesthesiology, Centro de Estudos e Pesquisas Oculistas Associados (CEPOA), Rio de Janeiro, Brazil

²Department of Ophthalmology, Centro de Estudos e Pesquisas Oculistas Associados (CEPOA), Rio de Janeiro, Brazil

³Department of Oculoplastics, Centro de Estudos e Pesquisas Oculistas Associados (CEPOA), Rio de Janeiro, Brazil

Email: *hugosiqueira@yahoo.com.br

How to cite this paper: Siqueira, H.C.T., De Siqueira, C.M.M.S., De Lima, M.M.B. and Lins, L.T.C. (2022) Ultrasound-Guided Peribulbar Block with Blunt Canula for Cataract Surgery: A Review of Historical Case-Series. *Open Journal of Ophthalmology*, 12, 322-334.

<https://doi.org/10.4236/ojoph.2022.123029>

Received: April 17, 2022

Accepted: August 27, 2022

Published: August 30, 2022

Copyright © 2022 by author(s) and Scientific Research Publishing Inc.

This work is licensed under the Creative Commons Attribution International License (CC BY 4.0).

<http://creativecommons.org/licenses/by/4.0/>



Open Access

Abstract

Introduction: Cataract surgery is one of the procedures most performed worldwide. Those are several options for anesthetic management, with many factors that affect the choice of any given technique, depending on patients' needs, surgeons' preferences and institutional facilities and processes. Although being more invasive than topic anesthesia, and with possible hazardous side effects, peribulbar block is still an effective and successful technique. The utilization of blunt canula and ultrasound guidance might enhance the safety pattern for this technique. **Methods:** This article presents a revision of 1089 consecutive cases from February 2016 to January 2022, of patients submitted to cataract surgery under peribulbar anesthesia with blunt canula and ultrasound guidance. **Results:** 1318 surgical records were selected, with 1089 filling the inclusion criteria. There was a higher prevalence of the feminine gender (54%), with a median age of 64.3 (28 - 102) years. Mean IAV was 2.9 mL (sd 0.16 mL, 2.5 - 3.0 mL), with total HOS 91.1%; OR to reach G2 or above for each (ISB/IMB) was 11.0; CA was 47.9%, with mean FAV of 4.29 mL (sd 2.17mL, 2.5 - 15 mL). In 8.9% patients, HOS could not be fully observed. ISB, IMB, CA and FAV were calculated for both groups (non-HOS and HOS-only). OR for CA (non-HOS/HOS-only) was 126.21. The main adverse effects were chemosis (2.9%), hyposphagma (5.7%) and high IOP (7.5%). No procedure was postponed due to anesthesia-associated adverse events. **Discussion:** This study points towards the feasibility of the described technique in an outpatient fashion, with low, mild and tolerable side effects associated.

Keywords

Cataract Surgery, Local Anesthesia, Ultrasound

1. Introduction

Cataract surgery is one of the oldest and most common procedures performed worldwide, and also one with the most success rate in medicine. The history of the many methods to treat the condition dates back to the fifth century BC, with the example of the couching technique, which was associated with many possible postoperative complications that could lead to irreversible blindness. Nowadays, technological advances allow patients of any age, with even severe clinical associated conditions to have the surgery performed in minutes, without the need for suturing, in an outpatient fashion, with safety and comfort. Evidently, the anesthesia techniques required to make these advances possible also have evolved through the decades [1] [2] [3].

Beyond the utilization of topic conjunctival cocaine for the couching procedure, passing by the time of venous, inhalatory or combined general anesthesia technique for the past complex procedures for cataract extraction, to the evolution of retrobulbar, and shortly after, peribulbar block, the advances bring back to the safe utilization of eye drops and minimum sedation to accomplish a possibly, non-complicated, five-minute minimally invasive surgery, in some centers [4] [5]. However, not all patients are suited to be submitted to wake topical anesthesia for facetectomy with phacoemulsification, an extremely delicate procedure, in which even the slightest involuntary eye, head or body movement could end with disastrous complications, and thus, there lies the place for peribulbar block and the balance between the indications regarding the depth of sedation/awareness and whenever to have motor block/deep sensitive eye block [6]. As most of the first peribulbar/retrobulbar anesthesia studies for eye surgery date to the 1960s, the evolution of needles and anesthetic solutions brings a specific range of options, with a wide safety profile, regarding possible adverse effects on the eye and its surroundings [7]. Therefore, despite the indication for one particularly complex, but quick and minimally invasive procedure, there is a possible conundrum regarding the anesthetic choice to ensure both an eventless and comfortable experience, as the merely use of a large needle in a non-cooperative patient could even impossibilite the surgery [3] [7] [8] [9]. The risk for potential adverse events associated with the block and the growing safety of topical anesthesia could appear to turn the evolutive direction towards the practice of minimum sedation and newer eye drops solutions, however, modern studies show that those risks can be mitigated, with the incorporation of advances in anesthesia care [3] [9].

Peribulbar anesthesia is an effective and successful technique, that is largely utilized for eye surgery, in many subspecialties, such as glaucoma, corneal, vi-

treoretinal and cataract surgery [3] [10]-[15]. It can provide deep, prolonged, surgical anesthesia and abolish involuntary or voluntary intraoperative eye movement, thus bringing not only safety, but comfort for both patient and surgeon [3] [7]. Its evolutionary story brings a heterogenic individually practice, and equally large possibilities of adverse effects, like eyelid hematomas, retrobulbar hemorrhage, increased intra-ocular pressure, chemosis, and eye deviation, among others, what could make an experienced surgeon attempt to avoid this anesthetic choice [3] [6] [8] [16]. Aside from this, constant advances in medicine expose a wider range of patients to eye surgery, as patients with mild to severe neurologic and cardiac conditions, or patients in the use of new antithrombotic agents that cannot be withdrawn, and many of them could benefit from having the operation under peribulbar block, as topical anesthesia is not free of its issues, as intra- and post-operative pain and involuntary or voluntary eye movements [3] [16] [17] [18]. The utilization of a sterile blunt canula, instead of a needle, may be hypothetically beneficial, as it could prevent unwittingly hemorrhagic accidents, which, with ultrasound guidance, could increase the safety profile of the procedure, in order to mitigate adverse events. This study brings a six-year experience review of the combined use of blunt canula with ultrasound guidance to peribulbar block for cataract surgery in a single center in Brazil.

2. Methods

2.1. Methodology

This study was conducted in the archives section of Centro de Estudos e Pesquisas Oculistas Associados, Rio de Janeiro, RJ, Brazil, after Institutional Review Board (IRB) stated that this work adhered to the tenets of the Declaration of Helsinki. Surgical records of 1318 patients submitted to cataract surgery under peribulbar block, from February 2016 to January 2022 were selected for evaluation and, after verification of eligibility criteria, 229 were excluded from the study. The remaining 1089, were suited to evaluation and enrolled in the study. It was utilized as inclusion criteria: complete records from patients above 18 years of age, submitted to cataract surgery under ultrasound-guided and blunt canula peribulbar block, with no previous adverse reactions related to iodine or any of the other substances utilized. As exclusion criteria it was utilized: patients less than 18 years of age, incomplete data and iodine or other utilized substance intolerance or documented allergic reaction. To graduate the depth of anesthesia, it was proposed two scales, one for sensitive and one for motor block evaluation. The sensitive degree was graduated at four stages: 0) no anesthesia; 1) only loss of palpebral tonus (which infer A fibers block, and so, also C fibers); 2) loss of painful reaction to iodine eye drops; 3) loss of proprioception of the eye drops. Akinesia was graduated at four stages: 0) no motor block; 1) loss of involuntary movement, but voluntary movement present or weak; 2) partial akinesia, where there is movement block, but not in all muscle territories; 3) total akinesia. The following data were submitted to statistical analysis: gender (male/female,

calculated by prevalence rate), age (years, calculated by median), initial anesthetic volume infusion bolus (IAV, in mL, overall mean and standard deviation—sd), typical ultrasonographic hypoechogenic signal during IAV (HOS, overall incidence rate), initial sensory block grade (ISB, incidence of each maximum ISB grade), initial motor block grade (IMB, incidence of each maximum IMB grade), complementary anesthesia necessary to achieve grade 2 for both sensory and motor block (CA, overall incidence), final anesthetic volume infused utilized on CA (FAV, in mL, overall mean and sd), supplementary sedation required lower RASS either to perform the block or during the surgery (SSa, during anesthesia, SSs, during the surgery, each incidence), and possible adverse events (each incidence) (**Table 1** and **Table 2**). Data extracted from the records were submitted to the statistical analysis software, IBM SPSS®.

Ultrasound positioning and image sequence are in **Figure 1**, while canula preparation is in **Figure 2**. Before engaging in the surgery, all submitted patients were asked to sign a consent form stating full awareness of both anesthetic and surgical process, with possible side effects and outcomes, along with authorization for publishing the results, with the due protection of their identities. Standard anesthetic technique is as follows:

All patients in supine position. It was utilized sterile 25 G × 38 mm blunt cannula and Mobissom® M4 wireless ultrasound 10 - 14 MHz, set to depth at 2 - 5 cm and a solution of Levobupivacaine 0.75% with hyaluronidasis at 15 IU/mL.

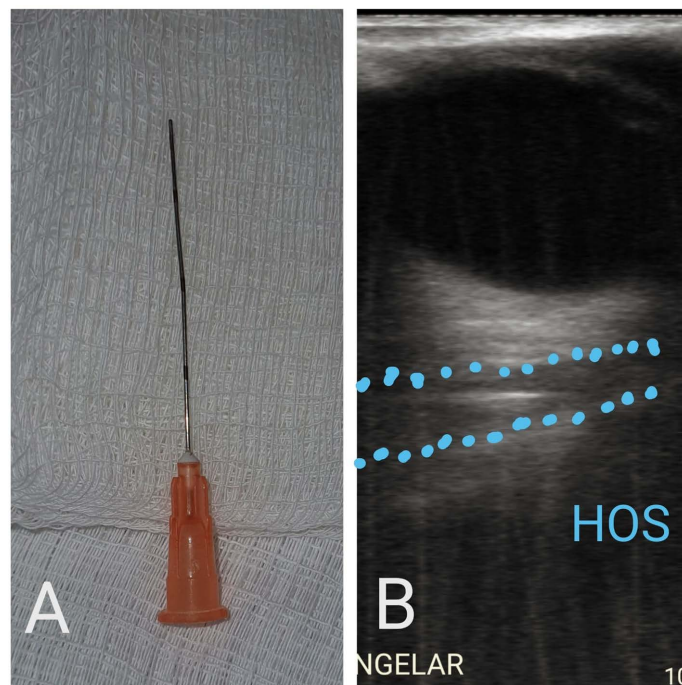


Figure 1. (A) 25 G × 38 mm blunt sterile cannula utilized in the process; (B) USG image after anesthetic infusion. It can be identified, from anterior to posterior, hydrophilic gel conductor, superior palpebral skin, anterior chamber, with capsular sac and cataract lens, posterior segment, and typical HOS, between posterior sclera and muscular layer. The cannula can be observed inside HOS, as a thin hyperechogenic line.

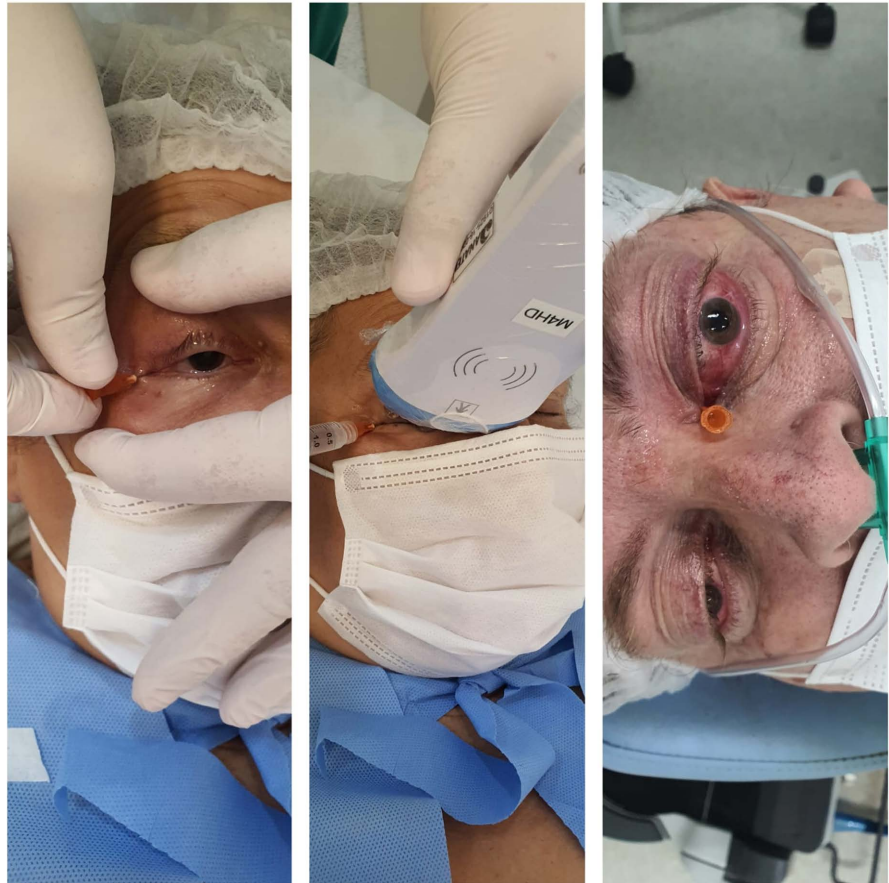

Figure 2. From left to right: canula insertion via inferior temporal; USG probe positioning; canula insertion via cantal medial (in the cases when supplementary anesthesia was necessary).

2.2. Technique

All patients had standard hemodynamic monitorization (HR, RR, ECG, NIABP and PO), intravenous access (hydration regimen with saline solution at 250 mL/h), supplementary oxygenation (nasal canula at 3 L/min), were sedated with midazolam 0.05 mg/kg and propofol 0.5 mg/kg and received 1% tetracaine eye drops, and 5% iodine eye drop preparation. Canula was inserted in the peribulbar space via inferior temporal (**Figure 2**) and had its positioning guided by ultrasonography, where the probe is initially at the transversal axial position, and mobilized to align with the canula direction. The correct visualization shows an *in plane* placement of the canula, posterior and oblique to the eye bulb, inside the muscular cone, at the minimum distance of 2 mm of the posterior scleral portion. Then, the anesthetic solution can be infused, and an hypoechogenic growing signal (HOS) can be observed inside the muscular cone, with its length proportional to the infusion rate, pushing the eye bulb anteriorly and the muscular internal wall of the cone towards the periosteum, therefore increasing the orbital structural volume. Then, light massage in the eye bulb was applied, in order to ease the dispersion of the anesthetic solution. When the patients were

awake, they were assessed to the degree of anesthesia, both motor and sensitive. Maximum initial anesthetic infusion was 3 mL. Patient was cleared to surgery with at least grade 2 for both sensitive and motor anesthesia. If complementary anesthetic infusion was required, it was chosen the medial cantal via, and small bolus of 1.5 mL following another light massage to the eye bulb and new clinical assessment for anesthesia degree was performed. This step would be repeated alternating the route of anesthetic administration (inferior temporal or medial cantal) until adequate anesthesia is achieved. At any time, if supplementary sedation was required to perform the block, another 0.5 mg/kg propofol bolus was administered. Results in **Table 1** and **Table 2**.

Patients were kept in Richmond Agitation-Sedation Score (RASS) 0 during the procedure. Additional propofol bolus at 0.1mg/kg was administered in case of RASS > 0, and sufentanyl or anesthetic eye drops in case of pain complaints. Post-operative nausea and vomiting (PONV) prophylaxis was given with ondansetron and dexamethasone, and analgesic prescription for postoperative period as “if necessary” was oral ketorolac 10mg single dose.

Hospitalar discharge happened when the patients were fully alert, hemodynamically stable with post-anesthetic scale score of 09 or above.

3. Results

From the initially 1318 surgical records, 1089 matched eligibility criteria. As exposed in **Table 1**, there was slightly higher prevalence of the feminine gender (54%), with the median age of 64.3 (28 - 102) years. Mean IAV was 2.9 mL (sd 0.16 mL, minimum 2.5 mL, maximum 3.0 mL), with total HOS 91.1%, meaning hypoechogenic signal observed in 991 patients during IAV; ISB was G0 0.46%, G1 6.9%, G2 62.2% and G3 30.4%; IMB was G0 3.8%, G1 42.9%, G2 47.8%, G3 5.4%; OR to reach G2 or above for each (ISB/IMB) was 11.0; CA was 47.9%, with mean FAV of 4.29 mL (sd 2.17 mL, min 2.5 mL and max 15.0 mL); SSa was 34.1% and SSs was 2.9%, meaning that 1 out of 33 patients required supplementary sedation to lower the RASS score during the surgery, with this protocol. In 98 (8.9%) patients, HOS could not be fully observed, despite adequate canula visualization, tissue movement visualization and/or initial HOS formation. ISB, IMB, CA e FAV were calculated to both groups (non-HOS and HOS-only), and the results were: (non-HOS) ISB G0 5.1%, G1 57.1%, G2 36.7%, G3 1.0%; (non-HOS) IMB G0 42.8%, G1 56.1%, G2 0%, G3 1.0%; (non-HOS) CA 98.9%; (non-HOS) FAV 9.9 mL (sd 1.99mL, min 3.0, max 15mL); (HOS-only) ISB G0 0%, G1 1.9%, G2 64.8%, G3 33.3%; (HOS-only) IMB G0 0%, G1 41.6%, G2 52.4%, G3 5.8%; (HOS-only) CA 41.6%, (HOS-only) FAV 3.74mL (sd 1.16 mL, min 2.5 mL, max 9.0 mL). OR for CA (non-HOS/HOS-only) was 126.21. The main adverse effects were chemosis (2.9%) and hyposphagma (5.7%). Chemosis were most observed after inferior-temporal infusion (90.6%), and hyposphagma was graduated in mild (restricted to injection site, 69.8%), moderate (reached anterior midline of the eye, 25.3%) and severe (crossed midline of the eye, 4.7%),

and it was most observed after cantal medial infusion (87.3%). 82 (7.5%) of overall patients were considered by the surgeon to have presented with increased intraoperative intraocular pressure, after a mean 9.09 mL (sd 2.60 mL, min 3.0

Table 1. Analytical data.

Gender (Male/Female)	501/588 (46/54%)
Age, yrs (mean)	64 (28 - 102)
IAV (mean, mil)	2.9 (sd 0.16 mL, 2.5 - 3.0 mL)
HOS	91.1%
ISB G0	5 (0.46%)
ISB G1	75 (6.9%)
ISBG2	678 (62.2%)
ISBG3	331 (30.4%)
IMB G0	42 (3.8%)
IMB G1	468 (42.9%)
IMB G2	520 (47.8%)
IMB G3	59 (5.4%)
CA	522 (47.9%)
FAV (mean, mL)	4.29 (sd 2.17mL, 2.5 - 15 mL)
SSa (yes/no)	371 (34.1%)
SSs (yes/no)	32 (2.9%)
(non-HOS) ISB G0	5 (5.1%)
(non-HOS) ISB G1	56 (57.1%)
(non-HOS) ISB G2	36 (36.7%)
(non-HOS) ISB G3	1 (1.0%)
(non-HOS) IMB G0	42 (42.8%)
(non-HOS) IMB G1	55 (56.1%)
(non-HOS) IMB G2	0 (0%)
(non-HOS) IMB G3	1 (1.0%)
(non-HOS) CA	97 (98.9%)
(non-HOS) FAV (mean, mL)	9.9 (sd 1.99 mL, 3.0 - 15 mL)
(HOS-only) ISB G0	0 (0%)
(HOS-only) ISB G1	19 (1.9%)
(HOS-only) ISB G2	642 (64.8%)
(HOS-only) ISB G3	330 (33.3%)
(HOS-only) IMB G0	0 (0%)
(HOS-only) IMB G1	413 (41.6%)
(HOS-only) IMB G2	520 (52.4%)
(HOS-only) IMB G3	58 (5.8%)
(HOS-only) CA	413 (41.6%)
(HOS-only) FAV (mean/mL)	3.7 mL (sd 1.16 mL, 2.5 - 9 mL)

OR calculated from overall ISB > 2/IMB > 2, and non-HOS-CA/HOS-only-CA.

Table 2. Adverse events.

Hyposphagma	Total rate: 62 (5.7%)		
	Mild	Moderate	Severe
	43 (69.8%)	16 (25.3%)	3 (4.7%)
	Infusion site predominance Medial cantal: 56 (87.3%)		
Chemosis	Total rate: 32 (2.9%)		
	Infusion site predominance Inferior temporal: 29 (90.6%)		
Intraoperative high IOP	82 (7.5%), after a mean 9.09mL (sd 2.60 mL, min 3.0 mL, max 13.5 mL)		

IOP = intra-ocular pressure.

mL, max 13.5 mL) and mannitol, 100 mg/kg bolus was administrated, with subjective clinical improvement. No procedure was postponed due to anesthesia-associated adverse event.

4. Discussion

Scientific advances in medicine tend to change the care towards better results, more safety and more comfort, both for physicians and patients. Therefore, the evolutionary history of cataract surgery shows an increasing population range, with either younger subjects or patients with more complexes or severe diseases and disabilities that could benefit from that procedure [3]. Each year, cataract extraction with intraocular lens implantation is performed in more than 300.000 patients in UK, 500.000 in France and over 2 million in the US, with virtually all procedures suited to happen in an outpatient fashion, mitigating expenses and risks related to hospitalization [1] [2] [3]. In 2012, Beketch *et al.* and also Duroi *et al.* in 2021, presented simplified surgical protocols, to create the processes without an anesthesiologist in the theater, due to the reduced number of those professionals, which was feasible and reproducible in higher scale, however, it brought another responsibility for the surgeon and the facilities, and could compromise safety and demanded both less complexes surgeries and patients [19] [20]. Seet *et al.* in 2018 even discussed if starvation regimens for the surgery could be more flexible, and concluded that, if patients were both at low risk for aspiration and low sedation requirement, they could benefit of no fasting, however, as the second is not a predictable variable, and there was no general consensus, it might be safer to maintain a fasting regimen [21]. Those examples mark that there is still a role for the anesthesiologist in the context of cataract surgery, as there are still complexities and heterogeneity that could demand a deeper state of sedation or just closer hemodynamic monitorization.

Regarding side effects related to LA and blockages, in 2016, Lee *et al.* [6], in a manuscript covering ophthalmic practice in UK during 13 months from 2012 to 2013, with an estimated number of 357.000 cataract surgeries, showed 7 globe perforations (sharp needle peribulbar anesthesia), 1 profound vasovagal episode (sharp needle peribulbar anesthesia), 1 silent myocardial infarction (subthenon

anesthesia), 1 cilioretinal artery occlusion (subthenon anesthesia), 1 anaphylaxis episode (subthenon anesthesia), 1 supraventricular tachycardia (sharp needle retrobulbar anesthesia) and 1 intraoperative and stromal oedema (topical anesthesia), in contrast with our study, that presented with no severe clinical or sight threatening complications, although the incidence of overall side effects was higher, which can be explained by those effects possibly not being accounted by the authors. Although that study was prospective, it was based on active search (survey questionnaire mailed to senior ophthalmologists), which was only returned by 49% of those professionals, therefore, also the number of side effects may be underreported. Alhassam and cols, in 2015 published a systematic review comparing retrobulbar with peribulbar block [8], in a huge contribution for scientific research in this field. The authors found a risk for conjunctival chemosis of 17.4% (98/563) in the peribulbar blocks and 7.1% (34/479) in the retrobulbar block group, both higher than the results from the present manuscript (2.9%), as the authors suggested that this difference could be caused by the more anterior and larger overall volume anesthetic delivery within the orbit. The mean volume of anesthetic solution used for the blocks was 8.3 ml and 4.7 ml, respectively, both higher than our overall mean (4.29 mL) and the mean for patients whom the hypoechogenic signal (HOS) was observed (3.7 mL), but lower than the patients whom HOS was not observed (9.9 mL). Retrobulbar hemorrhage was reported in 1/71 (0.3%) participants in the retrobulbar group, whereas our study did not present with any. Also, our study found 5.7% rate for hyposphagma, which is not found in the revision. However, there were studies with lower quality information excluded from the final analysis, also lowering the incidence of adverse effects.

As an important tool, regarding ultrasound thermal or mechanical safety, the eye has unique properties, such as high ultrasound absorption in the lens and orbital fat. According to FDA guidelines following the passage of the Medical Device Act of 1976, the maximum permissible acoustic energy intensity for ocular applications was 17 mW/cm² (spatial peak temporal average), but, with adoption of the Output Display Standard, this level was increased to 50 mW/cm², whereas acoustic power output being the primary determinant of the TI and MI (respectively, thermal index and mechanical index). According to the European Federation of Societies for Ultrasound in Medicine and Biology, the safe temperature increase is 1.5°C above physiological levels (derated spatial-peak temporal-average intensity—ISPTA 3), based on a model of ultrasound propagation in the eye [22]. King *et al.*' experimentation, in 2017 concluded that, with 10 Mhz and attenuation of 0.3 dB/cm-MHz, a 1.5°C temperature rise was not obtained until ISPTA 3 was above 435 mW/cm² [23]. The M4D Mobissom linear ultrasound dispositive, with the frequency of 10 - 14 Mhz and depth of 20 - 55 mm set with attenuation of 0.3 dB/cm-MHz fit the safety criteria, within the 10 s interval utilized for acquiring images, with the utilization of hydrophilic conductance gel between those intervals.

Jimenez *et al.* in 2012 successfully demonstrated the utilization of blunt canula for LA administration in soft tissues [24]. In 2020, Garcia and cols demonstrated that the utilization of an 18 G blunt canula was associated with a lower pain score during LA administration, and was non-inferior to a 26 G needle regarding hemorrhagic events [25]. The present study presents a safe utilization of a 25 G × 38 mm blunt canula.

With this model, it was possible to achieve adequate surgical anesthesia with low anesthetic infusion volume, in patients in whom the hypoechogenic signal was observed, however, there are still questions to be answered regarding the patients for whom the signal was not observed and required higher infusion volume. Fawal *et al.* in 2021, did not utilize USG guidance, having a higher infusion volume in the two groups of their study, as for Soares *et al.* in 2005, and Ripart *et al.* in 2001 [26] [27] [28]. In 2010, Cehajic-Kapetanovic *et al.* proposed a new method to grade either sensitive or motor ophthalmic blocks, in a study with heterogenic groups and also higher volumes, though the method utilized in this study was suggested to be easier to implement [29].

Patients were taken to a post-anesthesia unit after reaching 8 points or above on the Aldrete scale and cleared to have hospital discharge after reaching 09 points or above on the post-anesthetic scale [30] [31]. There was no clinical adverse event during the period.

5. Limitations of the Study

As a retrospective study, that was low generalization power. Also, the lack of randomization regarding the intervention could bring biases to the study.

6. Conclusion

After being stated its biases, this study enlightens hypothesis formulations. This manuscript was important to the better knowledge of the sonoanatomy of the eye and the adjustment for reproducibility of the anesthetic technique. Some answers need still to be investigated, such as how come some patients required higher infusion volumes and how could it be related to ultrasound images. It is still necessary for bigger studies to allow a better understanding of the process, and thus even more efficient approach.

Acknowledgements

CEPOA is an institution specialized in eye care, acting in the city of Rio de Janeiro, RJ, Brazil, for more than 60 years, with a vocation for education, certified by the Brazilian Council of Ophthalmology as a center for specialization in Ophthalmology and sub-specialization in Oculoplastics, among other subspecialties, having approximately 250 surgeries/month, between public service and private setting patients. Without the contribution of all personnel involved and patients that seek assistance, this data could not be generated.

Conflicts of Interest

The authors declare no conflicts of interest regarding the publication of this paper.

References

- [1] Jaffe, N.S. (1996) History of Cataract Surgery. *Ophthalmology*, **103**, S5-S16. [https://doi.org/10.1016/S0161-6420\(96\)30760-4](https://doi.org/10.1016/S0161-6420(96)30760-4)
- [2] Davis, G. (2016) The Evolution of Cataract Surgery. *Missouri Medicine*, **113**, 58-62.
- [3] McRae, L. and Presland, A. (2020) A Review of Current Ophthalmic Anaesthetic Practice. *British Medical Bulletin*, **135**, 62-72. <https://doi.org/10.1093/bmb/ldaa022>
- [4] Husted, R. and Johnson, R. (2002) History of Ophthalmic Anesthesia. In: Kumar, C., Dodds, C. and Fanning, G., Eds., *Ophthalmic Anaesthesia*, Swets and Zeitlinger, The Netherlands, 103-108.
- [5] Knapp, H. (1885) Cocaine and its Use in Ophthalmic and General Surgery. G.P. Putnam's Sons, New York, London.
- [6] Lee, R.M., Thompson, J.R. and Eke, T. (2016) Severe Adverse Events Associated with Local Anaesthesia in Cataract Surgery: 1 Year National Survey of Practice and Complications in the UK. *British Journal of Ophthalmology*, **100**, 772-726. <https://doi.org/10.1136/bjophthalmol-2015-307060>
- [7] Nouvellon, E., Cuvillon, P., Ripart, J. and Viel, E.J. (2010) Anaesthesia for Cataract Surgery. *Drugs & Aging*, **27**, 21-38. <https://doi.org/10.2165/11318590-000000000-00000>
- [8] Alhassan, M.B., Kyari, F. and Ejere, H.O.D. (2015) Peribulbar versus Retrobulbar Anaesthesia for Cataract Surgery. *Cochrane Database of Systematic Reviews*, No. 7, Article No. CD004083. <https://doi.org/10.1002/14651858.CD004083.pub3>
- [9] Fakhoury, H., Karama, H., Rizkallaha, P., Cherfana, C. and Arej, N. (2018) Brainstem Anesthesia after a Peribulbar Injection of Ropivacaine. *Journal Français d'Ophthalmologie*, **41**, e493-e494. <https://doi.org/10.1016/j.jfo.2018.03.018>
- [10] Vagge, A., Simonetti, F., Marengo, M., Burtolo, C., Musolino, M. and Traverso, C.E. (2021) Peribulbar Anesthesia for Strabismus Surgery in Adult Patients. *European Journal of Ophthalmology*, **31**, 3367-3371. <https://doi.org/10.1177/1120672120974947>
- [11] Yazici, B., Poroy, C. and Yayla, U. (2020) Combined Retro-Peribulbar and Subconjunctival Anesthesia for Evisceration Surgery. *International Ophthalmology*, **40**, 1-5. <https://doi.org/10.1007/s10792-019-01144-2>
- [12] Lessa, S. and Passarelli, C.A. (2007) Peribulbar Anesthesia for Blepharoplasty. *Aesthetic Plastic Surgery*, **31**, 463-466. <https://doi.org/10.1007/s00266-006-0240-3>
- [13] Ribeiro, J.A.S., Ribeiro, D.S., Scott, I.U., Abrão, J. and Jorge, R. (2020) Pain during Pars Plana Vitrectomy Following Sub-Tenon versus Peribulbar Anesthesia: A Randomized Trial. *PLOS ONE*, **15**, e0236624. <https://doi.org/10.1371/journal.pone.0236624>
- [14] Eke, T. (2016) Preoperative Preparation and Anesthesia for Trabeculectomy. *Journal of Current Glaucoma Practice*, **10**, 21-35. <https://doi.org/10.5005/jp-journals-10008-1198>
- [15] Agrawal, V. and Tharoor, M. (2002) Peribulbar Anaesthesia for Penetrating Keratoplasty. A Case Series. *Indian Journal of Ophthalmology*, **50**, 313-316.
- [16] Kong, K.L. and Khan, J. (2015) Ophthalmic Patients on Antithrombotic Drugs: A Review and Guide to Perioperative Management. *British Journal of Ophthalmology*,

- 99, 1025-1030. <https://doi.org/10.1136/bjophthalmol-2014-306036>
- [17] Makuloluwa, A.K., Tiew, S. and Briggs, M. (2019) Peri-Operative Management of Ophthalmic Patients on Anti-Thrombotic Agents: A Literature Review. *Eye*, **33**, 1044-1059. <https://doi.org/10.1038/s41433-019-0382-6>
- [18] Brooks, C.C., Venkateswaran, N., Cox, K. and Kim, T. (2020) Cataract Surgery in Patients with Left Ventricular Assist Devices. *Journal of Cataract & Refractive Surgery*, **46**, 1003-1006. <https://doi.org/10.1097/j.jcrs.0000000000000216>
- [19] De Beketch, C., Boissonnot, M., Bernit, A.-F., Debaene, B., Djabarouti, M., Bouamama, N. and Dighiero, P. (2013) Protocole simplifié de prise en charge anesthésique chez les patients opérés de cataracte sous topique: Étude rétrospective sur un an. *Journal Français d'Ophtalmologie*, **36**, 50-54. <https://doi.org/10.1016/j.jfo.2012.01.013>
- [20] Duroi, Q., Baudet, J.M., Bigoteau, M., Slim, M., Pichard, T., Pisella, P.J. and Khanna, R.K. (2021) Ambulatory Cataract Surgery Centre without Perioperative Anaesthesia Care: A Prospective Cohort Study. *Scientific Reports*, **11**, Article No. 8311. <https://doi.org/10.1038/s41598-021-87926-0>
- [21] Seet, E., Kumar, C.M., Eke, T. and Joshi, G.P. (2018) Starving Patients Before Cataract Surgery Under Regional Anesthesia: Needed or Not? *Anesthesia & Analgesia*, **127**, 1448-1451. <https://doi.org/10.1213/ANE.0000000000003504>
- [22] Acevedo, P. and Das-Gupta, D. (2002) The Measurement of the Spatial Average Temporal average Intensity Isata and Ultrasonic Power W in Composite Ultrasonic Transducers for Medical Application. *Ultrasonics*, **40**, 819-821. [https://doi.org/10.1016/S0041-624X\(02\)00218-4](https://doi.org/10.1016/S0041-624X(02)00218-4)
- [23] King, R.L., Liu, Y. and Harris, G.R. (2017) Quantification of Temperature Rise within the Lens of the Porcine Eye Caused by Ultrasound Insonation. *Ultrasound in Medicine & Biology*, **43**, 476-481. <https://doi.org/10.1016/j.ultrasmedbio.2016.09.021>
- [24] Jimenez, F. (2012) Blunt Needles (Microcannulae) for Infiltrating Local Anesthetics. *Dermatologic Surgery*, **38**, 511-512. <https://doi.org/10.1111/j.1524-4725.2011.02265.x>
- [25] Garcia, C.P., Avila, D.F.V., Ferreira, V.R.A., Silva, F.C.D., Fortkamp, M.M.S., Gomes, R.S. and Ely, J.B. (2021) Anesthesia Using Microcannula and Sharp Needle in Upper Blepharoplasty: A Randomized, Double-Blind Clinical Trial Evaluating Pain, Bruising, and Ecchymoses. *Journal of Plastic, Reconstructive & Aesthetic Surgery*, **74**, 364-369. <https://doi.org/10.1016/j.bjps.2020.08.015>
- [26] El Fawal, S.M., Nofal, W.H., Sabek, E.A.S. and Abdelaal, W.A. (2021) Minimum Effective Volume of Local Anesthetic in Peribulbar Block: Does It Differ with the Eyeball Axial Length? *Brazilian Journal of Anesthesiology*, **71**, 635-641. <https://doi.org/10.1016/j.bjane.2021.09.001>
- [27] Soares, L.F., Barros, A.C.M., Almeida, G.P., Boos, G.L. and de Oliveira Filho, G.R. (2005) Minimum Anesthetic Volumes for Extraconal Retrobulbar Block: Comparison between 0.5% Racemic Bupivacaine, Levobupivacaine and Enantiomeric Mixture s75/r25 Bupivacaine. *Revista Brasileira de Anestesiologia*, **55**, 263-265. <https://doi.org/10.1590/S0034-70942005000300002>
- [28] Ripart, J., Lefrant, J.Y., De La Coussaye, J.E., Prat-Pradal, D., Vivien, B., Eledjam, J.-J., et al. (2001) Peribulbar versus Retrobulbar Anesthesia for Ophthalmic Surgery: Anatomical Comparison of Extraconal and Intraconal Injections. *Anesthesiology*, **94**, 56-62. <https://doi.org/10.1097/00000542-200101000-00013>
- [29] Cehajic-Kapetanovic, J., Bishop, P.N., Liyanage, S., King, T., Muldoon, M. and Wearne, I.M. (2010) A Novel Ocular Anaesthetic Scoring System, OASS, Tool to Measure Both

Motor and Sensory Function Following Local Anaesthesia. *British Journal of Ophthalmology*, **94**, 26-30. <https://doi.org/10.1136/bjo.2008.155572>

- [30] Aldrete, J.A. and Kroulik, D. (1970) A Postanesthetic Recovery Score. *Anesthesia & Analgesia*, **49**, 924-934. <https://doi.org/10.1213/00000539-197011000-00020>
- [31] Palumbo, P., Tellan, G., Perotti, B., Pacile, M.A., Vietri, F. and Illuminati, G. (2012) Modified PADSS (Post Anaesthetic Discharge Scoring System) for Monitoring Outpatients Discharge. *Annali Italiani di Chirurgia*, **84**, 661-665.