



# Traumatic Bilateral Testicular Dislocation: A Case Report

**M. S. Soaid <sup>a\*</sup>, A. M. Mohamad <sup>a</sup> and M. N. Kamarulzaman <sup>a</sup>**

<sup>a</sup> Urology Unit, Department of Surgery, Sultan Ahmad Shah Medical Centre @IIUM, Jalan Sultan Ahmad Shah, 25200 Kuantan, Pahang, Malaysia.

## **Authors' contributions**

*This work was carried out in collaboration among all authors. All authors read and approved the final manuscript.*

## **Article Information**

### **Open Peer Review History:**

This journal follows the Advanced Open Peer Review policy. Identity of the Reviewers, Editor(s) and additional Reviewers, peer review comments, different versions of the manuscript, comments of the editors, etc are available here: <https://www.sdiarticle5.com/review-history/101502>

**Case Study**

**Received: 08/05/2023**  
**Accepted: 22/06/2023**  
**Published: 11/07/2023**

## **ABSTRACT**

Traumatic testis dislocation is a rare condition that usually occurs after direct scrotal trauma. We present a case of a young boy who presented with painful inguinal swelling and absent bilateral testes following genital trauma. Torsion of the left testis was discovered during scrotal exploration. Early detection and surgical intervention are critical because it raises the risk of future malignancy, decreased fertility, and endocrine dysfunction.

*Keywords: Traumatic bilateral; testicular; scrotal trauma.*

## **1. INTRODUCTION**

Testicular dislocation is a relatively rare complication that happens as a complication of blunt testicular trauma. It is regarded as the displacement of the testes from their natural location in the scrotal sac. It mainly occurs due to

straddle injuries in a motor vehicle accident. Manual reduction of a displaced testicle is a quick and straightforward treatment option, but it has a high failure rate and may ignore coexisting injuries. We report a case of bilateral testicular dislocation that happened to a child after trauma that led to testicular torsion.

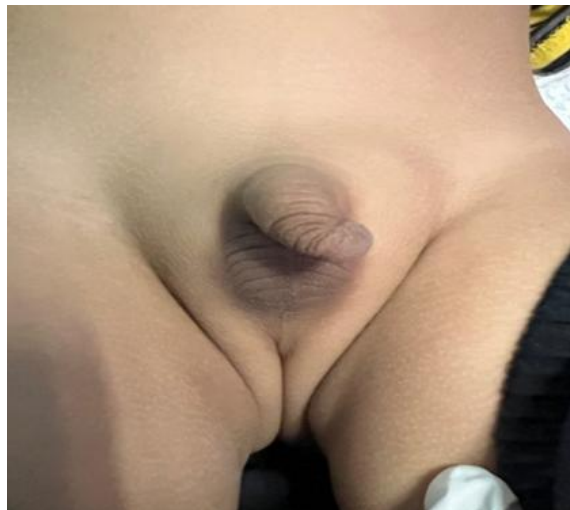\*Corresponding author: E-mail: shahimin89@gmail.com;

## 2. CASE REPORT

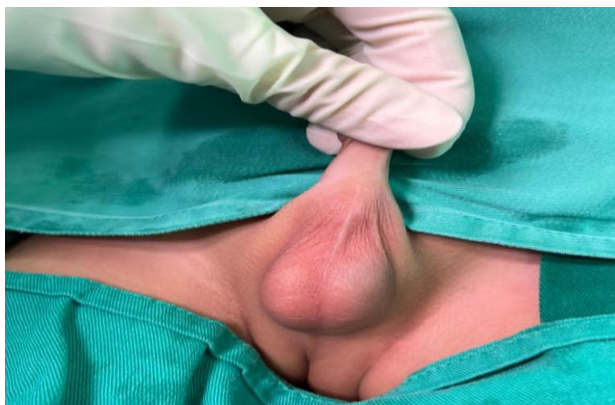
The patient was a 5-year-old boy with no medical illness who presented to the emergency department after sustaining trauma to his genital area. He claimed that his brother jumped on him and injured him in the genital area. Post-trauma, he complained of pain over his right inguinal area with the absence of both testes in the scrotum. There were lumps in both of his inguinal regions. It was associated with vomiting after the incident. Otherwise, he sustained no other injuries. He was alert, conscious, and hemodynamically stable on clinical examination. Vital signs were stable. An examination of the abdomen demonstrated a soft, non-tender abdomen with no signs of peritonitis. Examination of the genital area revealed empty scrotal sacs with tender mass in the bilateral inguinal area [Fig. 1]. A diagnosis of bilateral

testicular dislocation was made, and the patient was posted for bilateral scrotal exploration, keeping in mind of orchidopexy and orchidectomy.

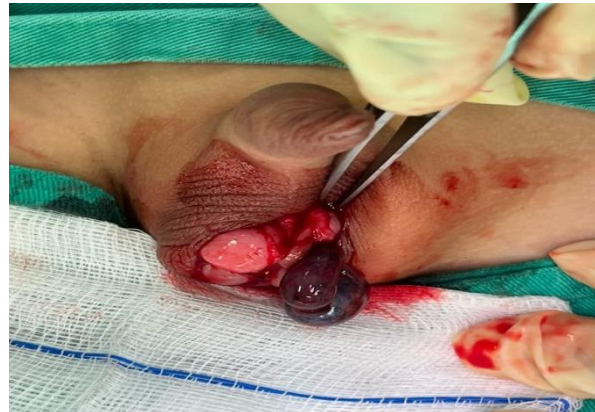The patient was placed under general anaesthesia in the operating room for bilateral scrotal exploration. Without any intervention, both testes spontaneously returned to the scrotum after induction [Fig. 2]. Nevertheless, the scrotum was explored via the median raphe approach. The right testis appeared normal intraoperatively. However, the left testis appeared gangrenous with a twisted cord and the presence of hematoma [Fig. 3]. The left testis was untwisted and resuscitated, unfortunately, the left testis showed no sign of viability, and a decision was made for orchidectomy while orchidopexy was performed on the right testis. Postoperatively, the patient recovered well.



**Fig. 1.** There are masses palpable at the bilateral inguinal area with empty of both scrotal sacs



**Fig. 2.** Both testes were spontaneously reduced back into the scrotum post-induction in the operation theatre



**Fig. 3. Intraoperatively showed normal appearance of the right testis with torsion and gangrenous of the left testis**

### 3. DISCUSSION

Testicular dislocation is defined as the displacement of a normally located testis out of the scrotal sac. It commonly occurs unilaterally but can be present bilaterally in about 30% of cases. The superficial inguinal area is the most common dislocation site, accounting for 50% of the cases. Other possible locations reported include the pubic, penile, canalicular, abdominal, perineal, acetabular, and crural regions [1]. Most of the patients had straddle injuries that resulted from motorcycle accidents in which the rider was thrust forward with the perineum and scrotum hitting the fuel tank or handlebar [2]. The factors contributing to the dislocation include the spasm of the cremasteric muscle that led to the retraction of the testis out of the hemiscrotal sac. Additional risk factors for this condition include underlying anomalies such as atrophied testes, an indirect inguinal hernia, and a wide external inguinal ring [3].

The clinical assessment of the patient should begin with a history and physical examination after the primary survey. In a patient without a history of orchiectomy or cryptorchidism, finding a painful, tender mass with displaced testes and an empty scrotum supports the diagnosis of this condition [4]. Ultrasonography is typically the initial imaging test conducted, and colour Doppler ultrasonography is beneficial for assessing the blood flow of the testis to rule out concurrent disorders such as testicular rupture, torsion, or epididymal avulsion and for determining the testicular vitality [2]. In a patient without a history of orchiectomy or cryptorchidism, finding a painful, tender mass with displaced testes and an empty scrotum supports the diagnosis of this condition [4].

A closed manual reduction may be tried if no concurrent testicular injury has taken place. However, due to scrotal wall oedema following trauma, it has only been reported successfully in about 15% of cases [5]. A case series by Kochakarm et al. from 1957 to 1997 revealed that only 14 out of 36 patients successfully underwent manual reduction under general anaesthesia for testicular dislocation [6]. Early surgical exploration was recommended because of the possibility of other coexisting testicular injuries and a failed manual reduction. Surgical intervention includes evacuation of hematoma, repair of lacerated tissue, fixation of testes after repositioning, and removal of testes if there is evidence of non-viable testes or gangrenous tissue [4]. Torsion, testicular ischemia, extensive atrophy of seminiferous tubules, significant impairment of spermatogenesis, and acute and persistent discomfort are potential complications that might occur when the diagnosis or treatment of testicular dislocations is delayed [7].

In our case, the patient presented to the emergency department 5 hours after the incident. Clinical examination showed tender swelling over the bilateral inguinal area with an empty scrotal sac. A diagnosis of testicular dislocation was made, and the patient was arranged for surgical exploration. After induction under general anaesthesia, both testes were spontaneously reduced into the scrotal sac. It might be due to the relaxation of the cremasteric muscle post-induction. Intra-operatively, the left testis showed torsion with gangrenous appearance. The left testis was removed because it was non-viable even after the trial of resuscitation [8,9]. The right testis was fixed to the dartos layer. The patient recovered and was discharged well.

#### 4. CONCLUSION

Although not immediately life-threatening, testicular dislocation is a rare injury that increases the risk of future malignancy, decreased fertility, and endocrine dysfunction. Early recognition and intervention are essential to avoid irreversible testicular injury.

#### CONSENT

As per international standard or university standard, patient(s) written consent has been collected and preserved by the author(s).

#### ETHICAL APPROVAL

As per international standard or university standard written ethical approval has been collected and preserved by the author(s).

#### ACKNOWLEDGEMENTS

We would like to express our gratitude to the patient's parents that gave their permission for this case report.

#### COMPETING INTERESTS

Authors have declared that no competing interests exist.

#### REFERENCES

1. Schwartz SL, Faerber GJ. Dislocation of the testis as a delayed presentation of scrotal trauma. *Urology*. 1994;43(5):743–745.  
Available: [https://doi.org/10.1016/0090-4295\(94\)90203-8](https://doi.org/10.1016/0090-4295(94)90203-8)
2. Tai YS, Chen YS, Wong WJ, Traumatic testicular dislocation: A rare occurrence of blunt scrotal injury, *Urological Science*. 2014;25(4):158–160.
3. Tai Y, Chen Y, Tsai P, Wong W. Traumatic testicular dislocation: A rare occurrence of blunt scrotal injury. *Urological Science*. 2014;25(4).  
DOI: 10.1016/j.urols.2014.04.001

3. Al Saeedi A, Khalil IA, Omran A, et al. A literature review and two case reports: Is traumatic dislocation of the testes a surgical emergency?. *Cureus*. (May 02, 2022);14(5):e24672.  
DOI:10.7759/cureus.24672
4. Nubyhélia Maria Negreiro de Carvalho, Ana Clemilda Ximenes Marques, Ivon Teixeira de Souza, Vanessa Guerreiro Soares, Felipe Gomes do Nascimento, Letícia Macedo Pinto, Luccas Victor Rodrigues Dias, Guilherme Carneiro Teixeira, "Bilateral Traumatic Testicular Dislocation. Case Reports in Urology. Article ID 7162351, 2018;2018:5.  
Available: <https://doi.org/10.1155/2018/7162351>
5. Perera E, Bhatt S, Dogra VS. Traumatic ectopic dislocation of testis. *Journal of clinical imaging science*. 2011;1:17  
Available: <https://doi.org/10.4103/2156-7514.77124>
6. Kochakarn W, Choonhaklai V, Hotrapawanond P, Muangman V. Traumatic testicular dislocation a review of 36 cases. *Journal of the Medical Association of Thailand = Chotmaihet thangphaet*. 2000;83(2),208–212.
7. Nistal M, Paniagua R, González-Peramato P, Reyes-Múgica M. Perspectives in pediatric pathology, chapter 23. testicular pathology secondary to physical and chemical injury. *Pediatric and Developmental Pathology*. 2016;19(6):452–459.  
DOI:10.2350/16-04-1811-PB.1
8. Sakamoto H, Iwasaki S, Kushima M, Shichijo T, Ogawa Y. Traumatic bilateral testicular dislocation: a recovery of spermatogenesis by orchiopexy 15 years after the onset. *Fertility and sterility*. 2008 Nov 1;90(5):2009–e9.
9. Smith CS, Rosenbaum CS, Michael Harris A. Traumatic bilateral testicular dislocation associated with an anterior posterior compression fracture of the pelvis: a case report. *Journal of surgical orthopaedic advances*. 2012 Jan 1;21(3):162.

© 2023 Soaid et al.; This is an Open Access article distributed under the terms of the Creative Commons Attribution License (<http://creativecommons.org/licenses/by/4.0>), which permits unrestricted use, distribution, and reproduction in any medium, provided the original work is properly cited.

Peer-review history:

The peer review history for this paper can be accessed here:  
<https://www.sdiarticle5.com/review-history/101502>